

Case Report

Atypical presentation and treatment of congenital cataract and temporal iridolenticular coloboma in a 43-year-old male

Rajwinder Kaur¹, Navreet Kaur¹, Harleen Kaur¹, Navdeep Kaur¹

¹Department of Ophthalmology, Adesh Institute of Medical Sciences and Research, Bathinda, Punjab, India.

ABSTRACT

Ocular coloboma occurs due to incomplete closure of the embryonic fissure in the 5th or 6th week of intrauterine life. Iris coloboma is characterised by a keyhole-shaped defect in the iris, typically located in the inferonasal quadrant. Temporal iris coloboma is a rare occurrence. Temporal iridolenticular coloboma is an uncommon structural anomaly within the iris that is sometimes linked to other ocular disorders, such as congenital cataracts. We describe a case study of a 43-year-old male patient who had a congenital cataract with temporal iridolenticular coloboma, which is not a common presentation. The aim is to report favourable outcomes of cataract surgery in patients with congenital cataracts associated with temporal iris coloboma with temporal lens coloboma. Phacoemulsification with intraocular lens implantation was done without any complications. Significant improvements in subjective visual function and visual acuity were seen in the post-operative follow-up.

Keywords: Congenital cataract, Iridolenticular, Coloboma, Cataract surgery, Phacoemulsification

INTRODUCTION

Ocular coloboma occurs due to defective closure of the embryonic fissure, typically happening between the 5th and 6th weeks of pregnancy. It can affect various parts of the eye, including the cornea, iris, zonules, ciliary body, choroid, retina and optic nerve. Its occurrence rate is 0.7/10,000 live births.^[1] The term 'typical *coloboma*' refers to defects observed in the inferior or inferonasal region of the fundus. Conversely, defects observed elsewhere are termed 'atypical coloboma'.^[2] A complete iris coloboma appears as an inferonasal defect that merges with the pupil, resembling a 'keyhole iris'.^[3]

A coloboma can span from the iris margin to the optic disc and encompass one or multiple defects along fusion lines. Colobomas impacting the posterior segment of the eye may influence one or both eyes, with around 60% of cases showing bilateral coloboma.^[4] If a coloboma is observed in the retinal pigment epithelium (RPE), neurosensory retina or choroid, it indicates that the posterior fetal fissure did not properly close. Individuals with this condition may have only sclera covering the RPE and may lack choroid. However, in certain instances, the retina may also be absent partially or completely.^[3] Iris involvement is frequent in eyes with fundus

coloboma, but this connection is not mandatory and does not necessarily correspond to the severity of the fundus coloboma.^[5]

Apart from this, it may be associated with inherited autosomal recessive rare eye diseases like retinitis pigmentosa.^[6] In addition, cataracts, lens subluxation, secondary glaucoma, amblyopia, strabismus and anisometropia have been linked to this developmental anomaly.^[7] In addition, these patients may also develop cataracts and experience dislocation of the crystalline lens.^[8] In cases where patients present with iris coloboma and cataracts, various surgical techniques, including intraocular lens (IOL) implantation, may be challenging.^[9]

CASE REPORT

A 43-year-old male presented with a progressive decline in visual acuity in both eyes since infancy, which has worsened over the past 2 years. Best-corrected visual acuity was finger-counting and projection of rays (PR) accurate in both eyes. The intraocular pressure of the right eye and the left eye were 11 and 12 mmHg, respectively. Both visual axes were well aligned with no nystagmus. Slit-lamp examination revealed the presence of dense bilateral congenital cataracts that were obstructing the

*Corresponding author: Rajwinder Kaur, Department of Ophthalmology, Adesh Institute of Medical Sciences and Research, Bathinda, Punjab, India. dr Rajwinder79@gmail.com

Received: 27 July 2024 Accepted: 17 September 2024 Epub Ahead of Print: 25 November 2024 Published: 07 January 2025 DOI: 10.25259/GJCSRO_38_2024

This is an open-access article distributed under the terms of the Creative Commons Attribution-Non Commercial-Share Alike 4.0 License, which allows others to remix, transform, and build upon the work non-commercially, as long as the author is credited and the new creations are licensed under the identical terms. ©2024 Published by Scientific Scholar on behalf of Global Journal of Cataract Surgery and Research in Ophthalmology

visual axis in both eyes. In addition, bilateral temporal iris and lens colobomas were also identified [Figure 1a and b]. On indirect ophthalmoscopy, a detailed fundus examination of both eyes was performed, which revealed no associated chorioretinal coloboma, as the cataract was central, so the peripheral non-opacified part of the lens allowed sufficient posterior segment examination. The interesting finding in this case is the unusual location of double iridolenticular coloboma without any associated retinochoroidal coloboma.

Given the complexity of this case, a tailored management strategy was essential. The primary goal was to address the congenital cataracts to improve the patient's visual acuity. Surgical intervention was planned with phacoemulsification and hydrophobic IOL implantation. In addition, the presence of lens colobomas required careful consideration during surgery to avoid further complications and to ensure optimal outcomes. Guarded visual prognosis consent was taken in view of suspected pre-existing amblyopia. Phacoemulsification with hydrophobic lens implantation was done in the left eye first. Best-corrected visual acuity in the left eye improved significantly from counting fingers to 6/12. After 1 week, the right eye was taken for phacoemulsification with IOL implantation, and best-corrected visual acuity improved to 6/9. By addressing the central cataracts, the overall quality of life of the patient improved significantly.

DISCUSSION

Iris colobomas frequently occur without any complications. The likelihood of colobomas being associated with systemic anomalies varies. There are two types of syndromes that coloboma may be associated with CHARGE syndrome (Coloboma heart defect, choanal atresia, retardation of growth and development, genital hypoplasia and ear abnormalities) Joubert syndrome (cerebellar vermis hypoplasia, oligophrenia, ataxia, coloboma and hepatic fibrosis syndrome).^[1] In the present case, no systemic abnormalities were found. Posterior embryotoxon has also been reported in association with double temporal retinochoroidal coloboma.^[10]

Colobomas often occur in the inferonasal quadrant of the eye; this location corresponds to the area where the optic fissure fails to close completely during embryonic development. Colobomas occurring in the temporal quadrant of the eye are less common compared to those in the inferonasal quadrant but can still occur.^[5] Temporal colobomas result from incomplete closure of the optic fissure during embryonic development in the temporal region of the eye. Temporal colobomas may affect structures such as the iris, choroid, retina and optic nerve in the temporal portion of the eye. They can lead to various visual impairments depending on the severity and extent of the colobomatous defect. To the best of our knowledge, an atypical temporal location with double coloboma has not been described.

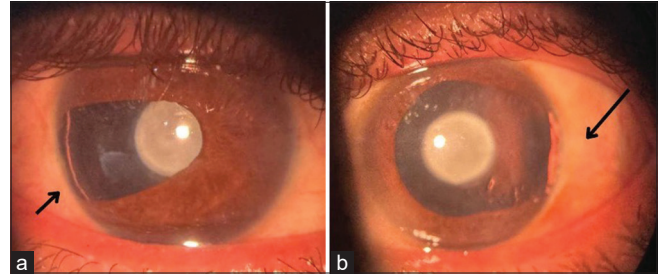


Figure 1: (a) Temporal iridolenticular coloboma (black arrow) with congenital cataract in the right eye (undilated pupil) and (b) temporal iridolenticular coloboma (black arrow) with congenital cataract in the left eye (dilated pupil).

Eyes with coloboma experience a higher rate of surgical complications such as poor pupil dilation, phacodonesis and zonular deficiency. Commencing capsulorhexis is difficult due to capsular instability. It is better to begin the capsulorhexis in the area where the zonules are whole and where the capsule offers sufficient resistance. If vitreous is present in the anterior chamber, it must be identified first by injecting diluted aurocort followed by vitrectomy if required. Nuclear phacoemulsification can be conducted using either coaxial phaco or bimanual phaco/phakonit, whether in the bag or out of the bag, based on the surgeon's preference. In general, phacoemulsification in these scenarios is considered safe if executed correctly.^[11] When performing automated aspiration, the tip movements should be non-radial to avoid the risk of traction on the colobomatous area and the capsular bag. The high-molecular-weight dispersive viscoelastic substance should be used over the colobomatous area to prevent misdirection of fluid during phacoemulsification.^[10]

Limitation

In our case, the patient had financial issues; hence, options like pupilloplasty or aniridia IOL could not be explored.

CONCLUSION

Each case requires careful evaluation and individualised treatment approaches to address the specific visual and anatomical abnormalities associated with coloboma.

Ethical approval

Institutional Review Board approval is not required.

Declaration of patient consent

The authors certify that they have obtained all appropriate patient consent.

Financial support and sponsorship

Nil.

Conflicts of interest

There are no conflicts of interest.

Use of artificial intelligence (AI)-assisted technology for manuscript preparation

The authors confirm that there was no use of artificial intelligence (AI)-assisted technology for assisting in the writing or editing of the manuscript and no images were manipulated using AI.

REFERENCES

1. Mushkani TA, Roheen ZU. Bilateral iris coloboma in an 11-year-old child with low vision and high intraocular pressure: A rare case report and review of literature. *Int Med Case Rep J* 2024;17:157-60.
2. Lingam G, Sen AC, Lingam V, Bhende M, Padhi TR, Xinyi S. Ocular coloboma-a comprehensive review for the clinician. *Eye* 2021;35:2086-109.
3. Warburg M. Classification of microphthalmos and coloboma. *J Med Genet* 1993;30:664-9.
4. Pavan-Langston D, editor. *Manual of ocular diagnosis and therapy*. United States: Lippincott Williams and Wilkins; 2008.
5. Gopal L, Badrinath SS, Kumar KS, Doshi G, Biswas N. Optic disc in fundus coloboma. *Ophthalmology* 1996;103:2120-6.
6. Amedome KM, Assavédo CR, Mensah YA, Dzidzinyo K, Vonor K, Ayéna KD, *et al.* Bilateral iris coloboma revealed by a decreased vision: About the first case in togo observed in Kara university teaching hospital. *Open J Ophthalmol* 2021;11:249-52.
7. Onwochei BC, Simon JW, Bateman JB, Couture KC, Mir E. Ocular colobomata. *Surv Ophthalmol* 2000;45:175-94.
8. Kim JH, Kang MH, Kang SM, Song BJ. A modified iris repair technique and capsular tension ring insertion in a patient with coloboma with cataracts. *Korean J Ophthalmol* 2006;20:246-9.
9. Cionni RJ, Karatza EC, Osher RH, Shah M. Surgical technique for congenital iris coloboma repair. *J Cataract Refract Surg* 2006;32:1913-6.
10. Dhillon HK, Narote KD, Agarkar S. Double temporal retinobulbar coloboma with posterior embryotoxon and persistent pupillary membrane: A case report. *J AAPOS* 2024;28:103818.
11. Kohli G, Shah C, Sen A, Joshi R, Sood D, Patidar N, *et al.* Cataract surgery in eyes with associated coloboma: Predictors of outcome and safety of different surgical techniques. *Indian J Ophthalmol* 2021;69:937-45.

How to cite this article: Kaur R, Kaur N, Kaur H, Kaur N. Atypical presentation and treatment of congenital cataract and temporal iridolenticular coloboma in a 43-year-old male. *Glob J Cataract Surg Res Ophthalmol*. 2024;3:113-5. doi: 10.25259/GJCSRO_38_2024