

Case Report

# Spontaneous separation of epiretinal membrane – A case report

Raunaq Poonia<sup>1</sup>, Mukesh Porwal<sup>1</sup>

<sup>1</sup>Retina Hospital, Rajkot, Gujarat, India.

## ABSTRACT

This study is aimed to report a rare case of epiretinal membrane (ERM) spontaneous separation with subsequent visual improvement. We are reporting a case of cellophane maculopathy with peripheral lattice degeneration with hole. Our examination revealed thick ERM associated with relatively high visual acuity (VA) 20/40, and laser barrage was done for lattice degeneration and watchful waiting strategy was chosen for the ERM. On follow-up after 1 month, slight visual deterioration to 20/60 was noted initially but on later visit, spontaneous ERM separation was noted and there was corresponding increase in visual acuity to 20/25, with decrease in retinal thickness demonstrated by optical coherence tomography (OCT). Such cases gives us additional evidence for deferring a surgery for management of patients with ERM with relatively high visual acuity.

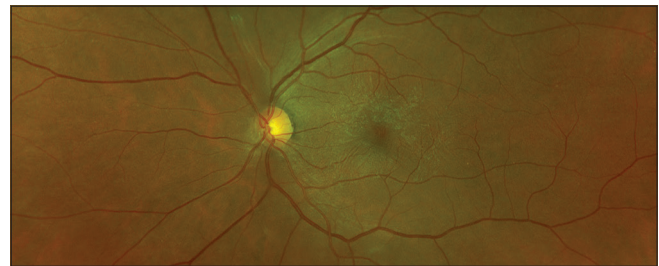**Keywords:** Epiretinal membrane, Cellophane maculopathy, Ectopic inner foveal layer, Spontaneous separation, Vitrectomy

## INTRODUCTION

Epiretinal membrane (ERM) is a common disease of vitreoretinal interface, presented by a sheet of avascular fibrocellular translucent tissue growing on an internal limiting membrane.<sup>[1,2]</sup> ERM is classified as idiopathic when it is not associated with intraocular inflammation, retinal vascular diseases, trauma, retinal detachment and retinal surgery and as secondary when it develops in connection with other ocular diseases.<sup>[2,3]</sup>

A mild ERM may not cause any visual symptoms. Symptomatic patients may experience blurred central vision that can significantly affect their quality of life.<sup>[4]</sup> Treatment for symptomatic ERM by pars plana vitrectomy and internal limiting membrane peeling results in significant improvement in visual symptoms in the majority of patients, although there is still the risk of postoperative complications.<sup>[4]</sup> Surgery is not always needed because symptoms may be minimal, spontaneous improvement may occur and delay in surgery often does not affect the end visual outcome.

Spontaneous separation of ERM from the retina is known to occur, although rarely, such an event may result in the improvement of visual symptoms in symptomatic patients. The regular use of optical coherence tomography (OCT) enables closer study of ERMs, particularly in asymptomatic patients. It also readily shows when spontaneous resolution occurs.



**Figure 1:** Optos colour picture showing cellophane reflex with a few retinal striae on the macula.

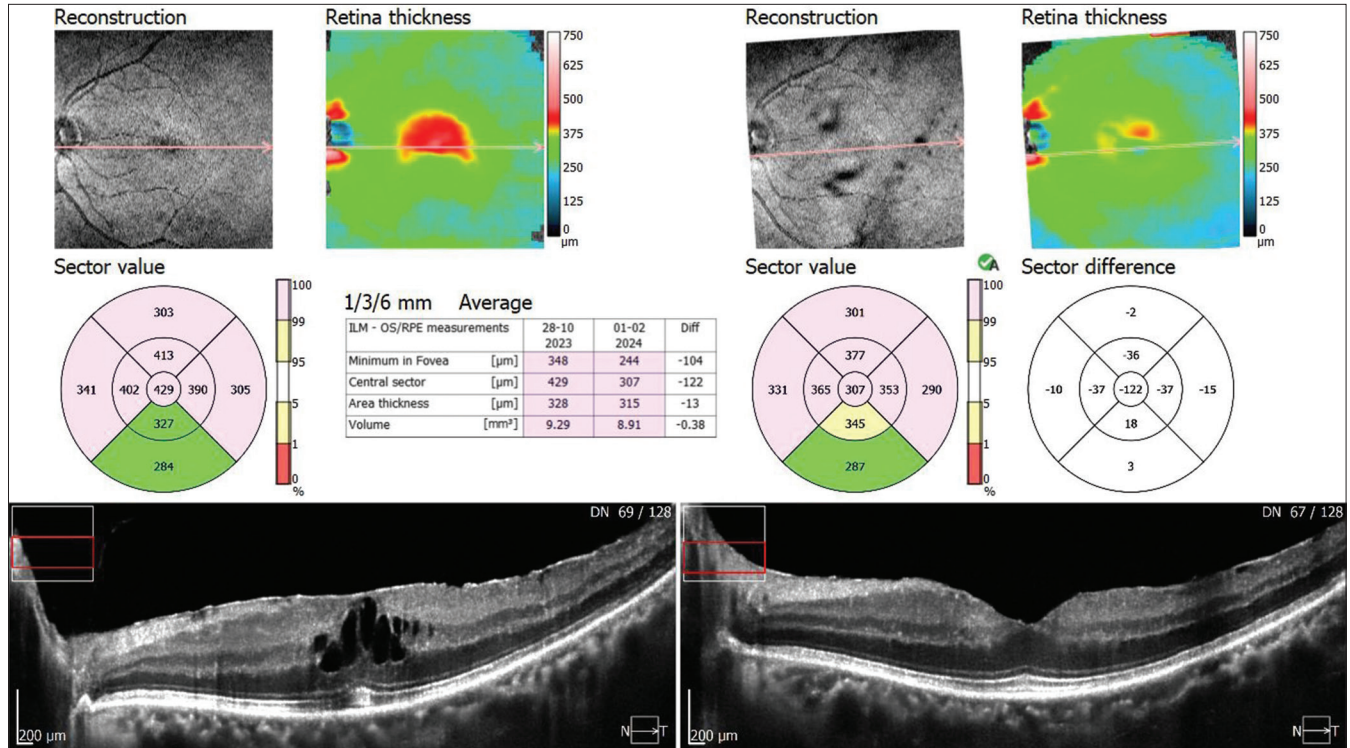
## CASE REPORT

A 65-year-old woman presented with 2 months of decreasing vision and flashes in her left eye. Visual acuity was 20/40 in the left eye and 20/20 in the right eye. Anterior segment evaluation and intraocular pressures were normal. Metamorphopsia was present on the Amsler grid in the left eye. Fundus examination revealed an incidental faint cellophane reflex with a few retinal striae on the macula with peripheral lattice degeneration with a hole in the left eye [Figure 1]. OCT disclosed a thin layer of hyper-reflectivity on the macular surface, confirming the presence of an ERM and diffuse retinal oedema. At this visit, a laser barrage was done for lattice degeneration, and a watchful waiting strategy was chosen for the ERM. During the follow-up after 1 month, slight visual deterioration was noted to 20/60 in the left and right eye was stable, but the patient did not undergo OCT examination.

\*Corresponding author: Raunaq Poonia, Retina Hospital, Rajkot, Gujarat, India. [raunaqpoonia9878@gmail.com](mailto:raunaqpoonia9878@gmail.com)

Received: 26 February 2024 Accepted: 09 July 2024 Epub Ahead of Print: 12 September 2024 Published: XXXXXXXX DOI: 10.25259/GJCSRO\_6\_2024

This is an open-access article distributed under the terms of the Creative Commons Attribution-Non Commercial-Share Alike 4.0 License, which allows others to remix, transform, and build upon the work non-commercially, as long as the author is credited and the new creations are licensed under the identical terms. ©2024 Published by Scientific Scholar on behalf of Global Journal of Cataract Surgery and Research in Ophthalmology



**Figure 2:** Comparative optical coherence tomography picture showing spontaneous separation of epiretinal membrane from the fovea with resolution of macular oedema. ILM: Internal limiting membrane, RPE: Retinal pigment epithelium, OS: Outer photoreceptor segment.

She returned 4 months later with a complaint of new-onset floaters and mild pain in her left eye for 2 days. Her best-corrected visual acuity improved to 20/25 in her left eye. Fundus examination revealed a Weiss ring and resolution of the previously noted retinal wrinkling. There was no new peripheral retinal break. OCT confirmed the disappearance of the ERM from the retinal surface and the presence of complete posterior vitreous detachment (PVD) with a slight decrease in the central foveal thickness in the left eye from 429  $\mu\text{m}$  to 307  $\mu\text{m}$  [Figure 2].

## DISCUSSION

Surgical removal of ERM results in visual improvement in 75–85% of eyes.<sup>[5,6]</sup> Conservative treatment of our patient obviates the need for surgery because the ERM spontaneously peeled across the fovea. This process may have been associated with PVD observed in our patient and supports previous similar observations.<sup>[7,8]</sup> PVD can be due to the barrage laser, which we have done for lattice degeneration, although we have not come across this in the literature. The non-surgical approach has been previously shown in the literature to result in improved vision in select circumstances.<sup>[9]</sup> Vision improved from 20/40 to 20/25 in our patient.

## CONCLUSION

Spontaneous ERM separation and improvement in visual symptoms is possible. Asymptomatic ERM patients or

those with mild symptoms can be managed conservatively. Regular structural assessment and monitoring of macular anatomy with OCT for spontaneous resolution of the ERM may help in deferring or avoiding surgery in some of these cases.

## Ethical approval

The Institutional Review Board approval is not required.

## Declaration of patient consent

The authors certify that they have obtained all appropriate patient consent.

## Financial support and sponsorship

Nil.

## Conflicts of interest

There are no conflicts of interest.

## Use of artificial intelligence (AI)-assisted technology for manuscript preparation

The authors confirm that there was no use of artificial intelligence (AI)-assisted technology for assisting in the

writing or editing of the manuscript and no images were manipulated using AI.

## REFERENCES

1. Steel DH, Lotery AJ. Idiopathic vitreomacular traction and macular hole: A comprehensive review of pathophysiology, diagnosis, and treatment. *Eye* 2013;27:S1-21.
2. Romano MR, Comune C, Ferrara M, Cennamo G, De Cillà S, Toto L., Retinal changes induced by epiretinal tangential forces. *J Ophthalmol* 2015;2015:372564.
3. Joshi M, Agrawal S, Christoforidis JB. Inflammatory mechanisms of idiopathic epiretinal membrane formation. *Mediators Inflamm* 2013;2013:192582.
4. Okamoto F, Okamoto Y, Hiraoka T, Oshika T. Effect of vitrectomy for epiretinal membrane on visual function and vision-related quality of life. *Am J Ophthalmol* 2009; 147:869-74.
5. Poliner LS, Olk RJ, Grand MG, Escoffery RF, Okun E, Boniuk I. Surgical management of premacular fibroplasia. *Arch Ophthalmol* 1988;106:761-4.
6. Donati G, Kapetanios AD, Pournaras CJ. Complications of surgery for epiretinal membranes. *Graefes Arch Clin Exp Ophthalmol* 1998;236:739-46.
7. Greven CM, Slusher MM, Weaver RG. Epiretinal membrane release and posterior vitreous detachment. *Ophthalmology* 1988;95:902-5.
8. Shirakawa H, Ogino N. Idiopathic epiretinal membranes with spontaneous posterior vitreous separation. *Ophthalmologica* 1987;194:90-4.
9. Gao H, Salam GA, Chern S. Spontaneous separation of idiopathic epiretinal membrane in a 7-year-old child. *J AAPOS* 2007;11:393-4.

**How to cite this article:** Poonia R, Porwal M. Spontaneous separation of epiretinal membrane – A case report. *Glob J Cataract Surg Res Ophthalmol*. doi: 10.25259/GJCSRO\_6\_2024