

## Original Article

# The prospective study of visual outcome in patients with isolated open-globe injuries

Shrushti Doshi<sup>1</sup>, Nitisha Sisodia<sup>1</sup>, Stuti Vikas Juneja<sup>1</sup>, Apurva Tushar Ghodichore<sup>1</sup>

<sup>1</sup>Department of Ophthalmology, Baroda Medical College, Vadodara, Gujarat, India.

## ABSTRACT

**Objectives:** The objective of this study was to study and predict factors affecting visual acuity in patients with open-globe injuries and determine the final visual acuity after intervention.

**Materials and Methods:** This prospective observational study was carried out on 30 patients of isolated open-globe injury involving cornea, sclera, lens, and iris, presenting to our hospital from January 2021 to October 2021. We recorded demographic data including age, sex, occupation, and a thorough history of the mode of injury including the type of object responsible for trauma. A detailed ophthalmic examination by recording pre-operative visual acuity, torch-light, and slit-lamp examination along with dilated funduscopy (wherever possible) was performed. Injuries were classified into zones I, II, and III. X-ray orbit was done for all patients to rule out associated intraocular foreign body and orbital fractures. All patients were given medical treatment in the form of local and systemic antibiotics and steroids. All patients underwent surgical intervention in the form of primary suturing repair of corneoscleral lacerations. Postoperatively, we monitored visual acuity daily and on follow-up visits after discharge.

**Results:** A total of 30 patients were enrolled based on the inclusion and exclusion criteria with the male-to-female ratio being 4:1. About 60% of injuries were attributed to agricultural and industrial professions, 16.67% to domestic mode, 13.33% to accidental and 10% to other modes like firecracker. The object responsible in the majority was wood (26.67%) followed by iron material (20%). Other objects responsible were metal, glass, firecrackers, etc. The right eye was more commonly involved than the left with the majority being a penetrating mode of trauma resulting in zone I injuries. Visual acuity was markedly reduced (<6/60) in 83.3% of patients preoperatively. About 60% of patients showed improvement in visual acuity after intervention with 40% having best-corrected visual acuity >6/60, 6 weeks after surgery, most of them belonging to the zone I category. We dichotomized the outcomes into two groups, improvement versus no improvement or deterioration, and carried out logistic regression taking the above factors into account. We assessed independent variables against the probability of obtaining improved visual acuity after 6 weeks and discovered that the type of open-globe injury was the only independent variable found to be significantly associated. Participants with ruptured open-globe injury had an adjusted odds ratio (aOR) of -0.91 ( $P = 0.023$ ).

**Conclusion:** It was hence concluded that the type of injury and the time of presentation significantly affect the visual outcome after surgery. Patients with a penetrating type of open-globe injuries showed improvement in visual acuity postoperatively. However, ruptured open-globe injuries were significantly predictive of non-improvement or deterioration of visual acuity after 6 weeks. This study provides comprehensive insights into the management and outcomes of open-globe injuries, highlighting the importance of prompt evaluation, appropriate treatment, and diligent follow-up care in optimising patient outcomes.

**Keywords:** Eye, Injuries, Open globe Management, Vision

## INTRODUCTION

Among the myriad of ocular afflictions, ocular trauma stands out as a significant cause of visual impairment and blindness, particularly among the younger population. Unlike age-related ocular diseases such as cataracts or macular degeneration, which predominantly affect older individuals, ocular trauma can strike an individual of any age, often with devastating consequences.

In the realm of ocular trauma, corneoscleral lacerations emerge as a particularly concerning entity, capable of causing extensive damage to the delicate structures of the eye.<sup>[1]</sup> The cornea, with its transparent and avascular nature, is the primary refractive surface of the eye, responsible for focusing incoming light onto the retina. The sclera, on the other hand, forms the tough outer shell of the eye, providing structural support and protection to the delicate intraocular contents.

\*Corresponding author: Stuti Vikas Juneja, Department of Ophthalmology, Medical College Baroda, Vadodara, Gujarat, India. [junejast@gmail.com](mailto:junejast@gmail.com)

Received: 11 April 2024 Accepted: 14 May 2024 EPub Ahead of Print: 12 July 2024 Published: XXXXXX DOI: 10.25259/GJCSRO\_16\_2024

This is an open-access article distributed under the terms of the Creative Commons Attribution-Non Commercial-Share Alike 4.0 License, which allows others to remix, transform, and build upon the work non-commercially, as long as the author is credited and the new creations are licensed under the identical terms. ©2024 Published by Scientific Scholar on behalf of Global Journal of Cataract Surgery and Research in Ophthalmology

When these structures are compromised by lacerations or perforations, the risk of vision loss and ocular complications escalates dramatically, underscoring the urgent need for intervention. Two types of errors occur in the evaluation of such injuries: Errors of commission and errors of omission. Errors of commission (performing surgery or prescribing medication that is contraindicated) are rare. More common are errors of omission, most frequently a failure to appreciate the true extent of the injury at the time of evaluation. The globe must be closed so that it is watertight with the original anatomy restored and the original function can be as closely approximated as possible.

The Ocular Trauma Classification Group<sup>[2]</sup> classified eye injuries based on four characteristics: Mechanism of injury, initial visual acuity, pupillary involvement, and most posterior location of the wound. This classification could be easily performed at the time of initial evaluation and primary injury repair.

Furthermore, the Birmingham eye trauma terminology<sup>[3]</sup> represents a significant advancement in the field of ocular trauma classification, offering clear definitions and standardised terminology for describing several types of ocular injuries.

The repair of corneoscleral perforations requires a systematic approach involving detailed history taking, thorough evaluation, and appropriate surgical techniques. Evaluation includes slit-lamp examination and imaging studies to assess the extent of injury and rule out complications. Pre-operative management involves antibiotic therapy and careful consideration of surgical principles to achieve watertight globe closure. Suturing techniques should target wound apposition while avoiding any induced astigmatism. For small perforations, non-surgical methods such as bandage contact lenses or glue application can be effective. Management of complications such as iris incarceration involves careful suturing techniques. Post-operative care includes antibiotics and corticosteroid therapy. Overall, adherence to these principles facilitates successful wound healing and visual recovery.

Hence, repairing corneoscleral perforations requires meticulous attention, precise surgical technique, and consideration of several factors to achieve optimal outcomes and preserve visual function. Hence, this study was undertaken to study and predict factors affecting visual acuity in open-globe injuries and to determine the final visual outcome after intervention.

## MATERIALS AND METHODS

The study conducted in a tertiary hospital in central Gujarat between 1 January 2021 and 31 October 2021 aimed to comprehensively evaluate patients with open-globe injuries.

Thirty patients with such injuries, involving the cornea, sclera, lens, and iris, were included in the study after obtaining ethical clearance from the Institutional Committee and informed consent from the patients. Patients with closed globe injuries, endophthalmitis, or previous eye surgeries were excluded from the study. Detailed demographic data, including age, sex, occupation, and type of trauma, were recorded for each patient, along with the duration between injury and hospital consultation. History of any primary treatment taken elsewhere after the trauma in the form of topical eye drops or systemic medication was inquired. A history of visual status before injury or a history of wearing glasses or ocular surgery was also asked for. History of other associated systemic illnesses such as diabetes and hypertension was recorded. Inquiry about the exact object causing the injury was done, and injuries were categorised into Zones I, II, and III; with the type of open-globe injuries such as penetrating, perforating, and rupture classified.

Patients underwent a thorough clinical examination, including an assessment of visual acuity, ocular structures, and intraocular pressure. The examination involved torchlight and slit-lamp examinations, dilated fundoscopy (wherever possible), and assessment of eyeball movements. Uncorrected visual acuity and best-corrected pre-operative visual acuity were recorded using Snellen's chart. Those who had a visual acuity <6/60 were then tested for finger counting. If this too was defective, then the hand movements, perception of light, and projection of rays were assessed. X-ray orbit was performed to detect associated foreign bodies or fractures. Systemic evaluations included basic tests such as blood sugar and blood pressure measurements.

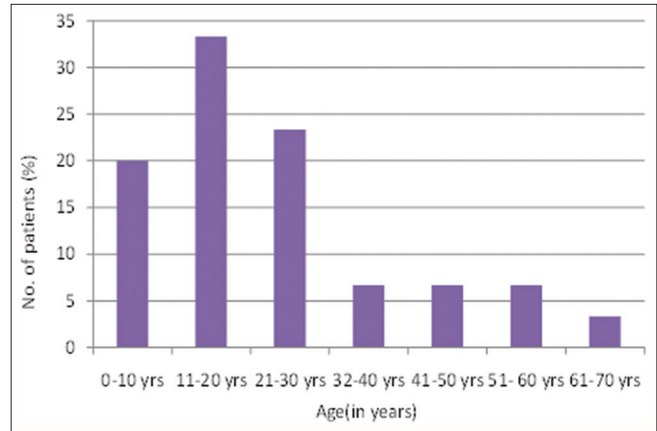
Medical treatment comprised local and systemic antibiotics, anti-inflammatory drugs, topical and systemic antifungals (wherever indicated), topical lubricants, and cycloplegics, while surgical intervention involved primary repair in the form of suturing of corneoscleral and conjunctival lacerations. Post-operative care included antibiotic and steroid therapy, intra ocular pressure (IOP)-lowering drugs, topical and systemic antifungals (wherever indicated), topical lubricants, cycloplegics, and measures to reduce corneal haze and oedema. Subconjunctival injections of dexamethasone and amikacin were administered in a few of the cases, along with topical medications.

Patients were closely monitored postoperatively, with daily examinations and dressing changes. Visual acuity, slit-lamp examination, and fundus evaluation were performed regularly until discharge. Follow-up appointments were scheduled at 1 week, 2 weeks, and 6 weeks, with additional assessments for patients with complications. Ultrasonography B-scan was conducted in cases of suspected vitreous haemorrhage or retinal detachment.

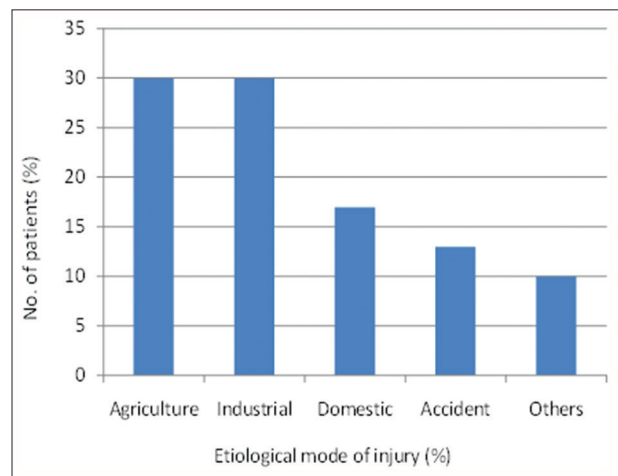
**RESULTS**

- The majority of the patients were male (80%). The male-to-female ratio was 4:1 in our study.
- The right eye (56.67%) was more commonly involved than the left eye (43.33%)
- The majority of patients had penetrating open-globe injury (53.33%) followed by rupture and perforating open-globe injuries which were 33.34% and 13.33% each, respectively.
- The youngest patient reported was 6 years and the eldest patient was 65 years old. Of the total male patients (24), the majority were in their 2<sup>nd</sup> decade (37.5%) of life, followed by 3<sup>rd</sup> decade (25%) and 1<sup>st</sup> decade (16.7%). Of the total female patients (6), the majority were in the 1<sup>st</sup> decade (33.33%) of their life [Figure 1].
- In the majority of the patients, agricultural injuries and industrial injuries were the major mode of injuries followed by others [Figure 2].
- The majority of injuries were caused by wood (26.67%), followed by iron material injury (20%) and others [Figure 3].
- The majority of patients were having zone I injury (43.33%). Patients with Zone II and Zone III injuries were 36.67% and 20% each, respectively.
- Pre-operative best-corrected visual acuity (BCVA) was markedly reduced (<6/60) in 25 patients (83.3%) [Table 1].
- Post-operative BCVA after 6 weeks was found to be <6/60 in 60% of patients and >6/60 in 40% of patients [Table 2].
- Post-operative complications: 33% of patients had no complications, traumatic cataract (16.67%), vitreous haemorrhage (16.67%), retinal detachment (13.33%), corneal opacity (6.67%) and phthisis bulbi (13.33%) were significant post-operative complications after 6 weeks.
- Visual acuity as 6-week follow-up: 60% of patients had improvement in visual acuity as compared to pre-operative visual acuity, 23% of patients had no improvement and 17% of patients had decreased visual acuity than that at the time of presentation.
- Logistic regression of factors affecting the final visual acuity is as follows:

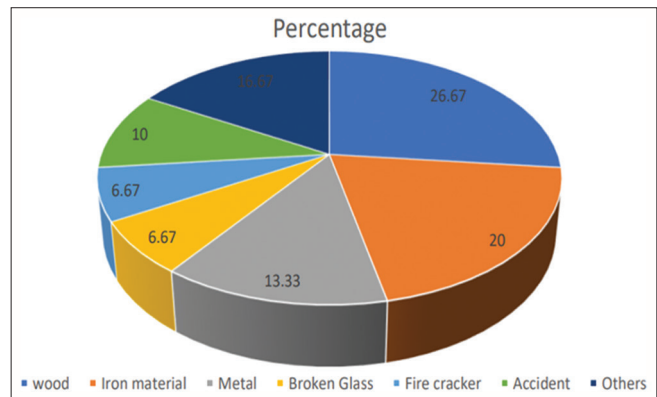
To understand the factors that were associated with a beneficial outcome at the end of 6 weeks, we dichotomised the outcomes into two groups – improvement versus no improvement or deterioration. Subsequently, we carried out logistic regression with all other pertinent factors (i.e. age, sex, occupation, mode of injury, and type of open-globe injury) as the independent variables. While conducting logistic regression, we took improvement in visual acuity as the reference and assessed independent variables against the probability of obtaining improved visual acuity at 6 weeks



**Figure 1:** Age distribution of patients in the present study.



**Figure 2:** Etiological mode of injury in our study.



**Figure 3:** Distribution of objects causing injury.

versus non-improvement/deterioration at 6 weeks. We found that the type of open-globe injury was the only independent variable that was found to be significantly associated with visual outcome at 6 weeks. We observed that participants with ruptured open-globe injuries had an aOR of -0.91 (95% Confidence interval: -1.7, -0.14, *P* = 0.023) of improvement

**Table 1:** Pre-operative visual acuity on presentation.

Pre-operative best-corrected visual acuity	Number of patients	Percentage
6/9	1	3.33
6/12	1	3.33
6/18	0	0
6/24	1	3.33
6/36	0	0
6/60	2	6.67
<6/60	6	20
HM	2	6.67
PL+	17	56.67
Total	30	100

HM: Hand Movements, PL: Perception of Light

**Table 2:** Post-operative best-corrected visual acuity at 6 weeks.

Post-operative best-corrected visual acuity	Number of patients	Percentage
6/6	2	6.67
6/9	0	0
6/12	3	10
6/18	3	10
6/24	3	10
6/36	0	0
6/60	1	3.33
<6/60	4	13.33
HM	5	16.67
PL+	7	23.33
No PL*	2	6.67
Total	30	100

\*There was no perception of light as the eye went into phthisis following the repair, HM: Hand Movements, PL: Perception of Light

in visual acuity at 6 weeks. In other words, rupture open-globe injury is significantly predictive of non-improvement/deterioration of visual acuity at 6 weeks. On assessing model fit, we found that the R2 for the model was 0.58, while the adjusted R2 was 0.24. However, the overall significance (P-value) of the model was found to be 0.1534, indicating that the model is non-significant [Table 3].

## DISCUSSION

Our study on open-globe injuries conducted at a tertiary hospital in central Gujarat provides valuable insights into the epidemiology, clinical characteristics, and outcomes of patients with these injuries, comparing the findings with those of other relevant studies.

The study conducted by Toh *et al.*<sup>[4]</sup> found that 76.2% of male patients experienced ocular trauma of the open-globe type. Similarly, Ustaoglu *et al.*<sup>[5]</sup> and Rao *et al.*<sup>[6]</sup> observed that 79% and 90% of patients with open-globe injuries, respectively,

**Table 3:** Logistic regression of factors affecting the final visual acuity.

Factor	Beta	95% Confidence Interval	P-value
Age	-0.01	-0.04, 0.02	0.6
Sex			
Female	-	-	-
Male	0.92	-0.36, 2.2	0.15
Occupation			
Factory worker	-	-	-
Farmer	1.1	-1.4, 3.5	0.4
Housewife	1.1	-1.1, 3.3	0.3
Labourer	-0.25	-1.4, 0.90	0.7
Student	-0.57	-2.2, 1.1	0.5
Watchman	1.2	-1.0, 3.3	0.3
Mode of injury			
Accident	-	-	-
Agriculture	-0.71	-1.9, 0.47	0.2
Domestic	-0.58	-1.9, 0.69	0.3
Industrial	-0.92	-2.1, 0.26	0.12
Others	-0.19	-1.5, 1.1	0.8
Type of Open Globe Injury			
Penetrating	-	-	-
Perforating	0.02	-0.84, 0.89	>0.9
Rupture	-0.91	-1.7, -0.14	0.023

were male. Our study confirms a male predominance in open-globe injuries, with 80% of the patients being male. This finding is in agreement with previous research indicating that males are more susceptible to ocular trauma due to increased exposure in occupational and outdoor settings.

The study reveals that patients below 40 years of age accounted for the majority (83%) of open-globe injuries. This aligns with findings from other studies, highlighting the higher risk of ocular trauma in younger individuals, possibly due to greater involvement in activities associated with trauma.

Agricultural and industrial injuries were the most common causes of open-globe injuries in the present study, which too has been reported in the findings of previous research. This underscores the importance of implementing preventive measures and safety protocols in these high-risk environments to reduce the incidence of ocular trauma. Misra *et al.*<sup>[7]</sup> showing that agricultural injuries (43.3%) are the most common cause of ocular trauma. Thevi *et al.*<sup>[8]</sup> found that the majority of injuries occurred at the workplace (36.5%).

Gogate *et al.*<sup>[9]</sup> found that 28% of cases of injuries were due to wooden sticks and Misra *et al.*<sup>[7]</sup> studied that in 21.05% of cases, injuries were caused by a wooden stick. In our study too, wooden sticks were the major causative object. A probable reason for this could be that most of our patients were from rural areas where patients acquired wooden stick injuries during work.

Penetrating injuries accounted for the majority (53.33%) of open-globe injuries in the study, consistent with previous research indicating that penetrating injuries are the most common type of ocular trauma. Court *et al.*<sup>[10]</sup> found that 56.4% of open-globe injuries were of penetrating type followed by globe rupture (35.6%). Ustaoglu *et al.*<sup>[5]</sup> found that 75% of open-globe injuries were penetrating type. In our study too, 53.33% of open-globe injuries were of penetrating type.

Zone I injuries were the most common in the present study, similar to the results of other studies like Rao *et al.*<sup>[6]</sup> where 53% of open-globe injuries were in zone I and Ustaoglu *et al.*<sup>[5]</sup> found that patients with penetrating injury and zone I injury among all injury zones had the highest visual acuity. This emphasizes the importance of precise localisation of the injury for optimal management and prognostication.

The study indicates that a considerable proportion of patients presented with poor pre-operative visual acuity, with 63.3% having vision ranging from hand movement to perception of light. Toh *et al.*,<sup>[4]</sup> studied 42 patients with open-globe injuries and 61.9% patients of them had pre-operative vision hand movement to perception of light. In the present study, 63.3% of patients had pre-operative vision hand movement to perception of light.

However, postoperatively, there was an improvement in visual acuity, with 40% of patients achieving final visual acuity ranging from hand movements to perception of light. These findings underscore the importance of timely intervention and appropriate management in optimising visual outcomes in patients with open-globe injuries.

The present study corroborates the study conducted by Toh *et al.*<sup>[4]</sup> in which they studied 42 patients with open-globe injuries and 40.5% patients of who had final vision hand movement to the perception of light. In the present study, 40% of patients had final visual acuity of hand movement to perception of light. Court *et al.*<sup>[10]</sup> found that 46% of patients achieved a final BCVA of >6/12. Guven *et al.*<sup>[11]</sup> observed that final visual acuity >6/60 in 49.3% of their patients.

Our study reports post-operative complications such as retinal detachment and phthisis bulbi in 13.33% of cases, highlighting the challenges associated with managing open-globe injuries and the importance of close monitoring for complications. This could also be a contributing factor to poor visual outcomes in our patients.

Overall, the discussion emphasizes the study findings of previous research, highlighting key epidemiological trends, causative factors, injury patterns, and visual outcomes in patients with open-globe injuries. By comparing the study findings with those of other relevant studies, the discussion provides valuable insights into the broader

context of ocular trauma research and contributes to our understanding of the management and outcomes of open-globe injuries. Further, the delay in the presentation of such serious injuries can also be attributed to the attitude of the rural population which increases the complication rate many fold.

### Limitations

Our present study had a small sample size, so it might be difficult to apply the results to the general population. Moreover, most of our patients belonged to a lower socioeconomic group and agricultural industry which could have directly affected the parameters such as mode and object of injury.

### CONCLUSION

Ocular trauma represents a significant public health concern, with the potential to cause profound and lifelong disabilities and to highlight the key points in a nutshell:

- Addressing ocular injuries requires a coordinated effort among healthcare professionals, encompassing accurate classification, precise prognostication, and meticulous surgical management.
- The primary aim of surgical management is rapid closure, attainment of a water-tight compartment, and restoration of normal anatomy as closely as possible.
- The final visual acuity largely depends on the mechanism of the trauma, the location of the wound, and the damaged ocular structures.

Thus, by leveraging advanced classification systems, prognostic tools, and surgical techniques, clinicians can mitigate the impact of ocular trauma and preserve visual function, thereby enhancing the quality of life for affected individuals.

### Ethical approval

The research/study was approved by the Institutional Review Board at Baroda Medical College and SSG Hospital, Baroda, number IECBHR/50-2021, dated 19 March 2021.

### Declaration of patient consent

The authors certify that they have obtained all appropriate patient consent.

### Financial support and sponsorship

Nil.

### Conflicts of interest

There are no conflicts of interest.

### Use of artificial intelligence (AI)-assisted technology for manuscript preparation

The authors confirm that there was no use of artificial intelligence (AI)-assisted technology for assisting in the writing or editing of the manuscript and no images were manipulated using AI.

### REFERENCES

- Garg A, Sachdev MS, Bovet JJ, Shukla B. Clinical diagnosis and management of ocular trauma. 1<sup>st</sup> ed., Ch. 1., Sec. 1. New Delhi: Jaypee Brothers Medical Publishers; 2009. p. 5.
- Kuhn F, Maisiak R, Mann L, Mester V, Morris R, Witherspoon CD, *et al.* The ocular trauma score (OTS). *Ophthalmology* 2002;109:845-50.
- Birmingham Eye Trauma Terminology (BETT) Committee. The Birmingham Eye Trauma Terminology system (BETT). *J Am Assoc Pediatric Ophthalmol* 2012;16:185-6.
- Toh ZH, Agrawal S, Rajee D, Hoskin A, Agrawal R, Khandelwal R. International globe and adnexal trauma epidemiology study (IGATES): A report from Central India on visual outcome in open globe injuries and correlation with ocular trauma score. *Int Ophthalmol* 2020;40:2797-806.
- Ustaoglu M, Karapapak M, Tiryaki S, Dirim AB, Olgun A, Duzgun E, *et al.* Demographic characteristics and visual outcomes of open globe injuries in a tertiary hospital in Istanbul, Turkey. *Eur J Trauma Emerg Surg* 2020;46:549-56.
- Rao LG, Ninan A, Rao KA. Descriptive study on ocular survival, visual outcome and prognostic factors in open globe injuries. *Indian J Ophthalmol* 2010;58:321-3.
- Misra S, Nandwani R, Gogri P, Misra N. Clinical profile and visual outcome of ocular injuries in a rural area of western India. *Australas Med J* 2013;6:560-4.
- Thevi T, Mimiwati Z, Reddy SC. Visual outcome in open globe injuries. *Nepal J Ophthalmol* 2012;4:263-70.
- Gogate P, Sahasrabudhe M, Shah M, Patil S, Kulkarni A. Causes, epidemiology and long-term outcome of traumatic cataracts in children in rural India. *Indian J Ophthalmol* 2012;60:481-6.
- Court JH, Lu LM, Wang N, McGhee CN. Visual and ocular morbidity in severe open-globe injuries presenting to a regional eye centre in New Zealand. *Clin Exp Ophthalmol* 2019;47:469-77.
- Güven S, Durukan AH, Erdurman C, Kucukcilioglu M. Prognostic factors for open-globe injuries: Variables for poor visual outcome. *Eye (Lond)* 2019;33:392-7.

**How to cite this article:** Doshi S, Sisodia N, Juneja SV, Ghodichore AT. The prospective study of visual outcome in patients with isolated open-globe injuries. *Glob J Cataract Surg Res Ophthalmol*. doi: 10.25259/GJCSRO\_16\_2024