

## Case Report

# A rare case of pyelonephritis-associated endogenous endophthalmitis

Sarjak Maulik Shah<sup>1</sup>, Dixa Narinder Suthar<sup>1</sup>, Khyati Shailesh Mehta<sup>1</sup>, Purvi Raj Bhagat<sup>1</sup>

<sup>1</sup>Department of Ophthalmology, M and J Institute of Ophthalmology, Ahmedabad, Gujarat, India.

## ABSTRACT

Endogenous endophthalmitis (EE) is the inflammation of the inner layers of the eye occurring due to intraocular colonisation of microorganisms from a pre-existing systemic septic foci. It is relatively rare and is most often associated with diabetes mellitus, liver disease, cardiac disease, malignancy, indwelling catheters and intravenous drug abuse. We report here a rare association of EE and pyelonephritis in a young male. The clinical condition and visual acuity improved first with topical, systemic and periocular corticosteroids, broad spectrum antibiotics, later by pars plana vitrectomy and ultimately with ureteric stenting. Prompt and multidisciplinary management along with accurate clinical history, thorough examination, and microbiological and radiological corroboration can help to prevent visual handicaps.

**Keywords:** Infectious endophthalmitis, Endogenous endophthalmitis, Pyelonephritis, Intravitreal injections, Pars plana vitrectomy

## INTRODUCTION

Endogenous endophthalmitis (EE) is a visually devastating consequence of a systemic infection caused most commonly by virulent bacteria or fungi. It comprises of almost 2–8% of all cases of endophthalmitis.<sup>[1]</sup> Its outcomes are dictated by the timely detection of the offending organism, virulence of the pathogen, immunity of the host and prompt initiation of aggressive and targeted treatment. In general, the outcomes are better with yeast than with molds, and worst with bacteria.<sup>[2]</sup>

Here, we report a case of a 26-year-male patient with a history of enteric fever and associated pyelonephritis with presence of concurrent ocular inflammation in the left eye (LE). The patient was started initially on conservative treatment with topical and systemic broad spectrum antibiotics and steroids, following which partial resolution of inflammation was noted. A pars plana vitrectomy for removal of the organised exudates in the vitreous cavity proved to be effective along with definitive treatment of the nephrological condition. Cases have been reported of EE associated with enteric fever<sup>[3]</sup> but those with pyelonephritis are rare.<sup>[4]</sup>

## CASE REPORT

A 26-year-male patient presented with complaint of sudden diminution of vision associated with pain and redness in his

LE for 4 days. He had no other ocular complaints in the same or fellow eye. He gave history of enteric fever 10 days before presentation for which he had taken three doses of 1 g Intravenous (IV) Ceftriaxone and supportive IV fluids. He had complained of radiating, colicky and intermittent back pain in his left flank region for 1 week for which no treatment had been taken.

On examination, the visual acuity (VA) in his right eye (RE) was 6/6 unaided on the Snellen's distant VA chart and hand movements (HM) with perception of light (PL) present in his LE, not improving with glass or pinhole. On slit lamp examination, there was marked circumciliary and conjunctival congestion, diffuse corneal oedema, significant anterior chamber (AC) inflammation (+3 cells according to standardisation of uveitis nomenclature criteria) with an inflammatory membrane covering the pupillary area, 1 mm hypopyon [Figure 1], few posterior synechiae and a cataractous lens in the LE. Patient was subjected to fundus examination using indirect ophthalmoscopy which revealed little information due to compromised corneal and lenticular transparency. B scan ultrasonography (USG) was performed which showed moderate to high intensity echoes in anterior and mid vitreous cavities [Figure 2]. RE was normal in all respects. The extraocular movements in both the eyes were full and the Goldmann appplanation intraocular pressure in the right and LE was 14 and 19 mm Hg, respectively.

\*Corresponding author: Sarjak Maulik Shah, Department of Ophthalmology, M and J Institute of Ophthalmology, Ahmedabad, Gujarat, India. [sarjakmshah@gmail.com](mailto:sarjakmshah@gmail.com)

Received: 21 February 2023 Accepted: 03 April 2023 Published: 09 June 2023 DOI: 10.25259/GJCSRO\_2\_2023

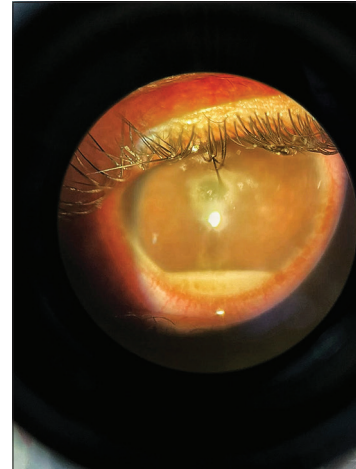This is an open-access article distributed under the terms of the Creative Commons Attribution-Non Commercial-Share Alike 4.0 License, which allows others to remix, transform, and build upon the work non-commercially, as long as the author is credited and the new creations are licensed under the identical terms. ©2023 Published by Scientific Scholar on behalf of Global Journal of Cataract Surgery and Research in Ophthalmology

With a preliminary diagnosis of EE, the patient was started on prednisolone acetate (1%) eye drops 1 hourly, moxifloxacin (0.5%) eyedrops 4 times a day, atropine (1%) eye ointment thrice a day and brimonidine (0.2%) with timolol (0.5%) eyedrops twice daily. A sub-conjunctival injection of 0.5 cc dexamethasone and 0.5 cc gentamicin was also given to the patient on presentation along with a diagnostic vitreous tap (biopsy) and intravitreal injections of imipenem (100 µg/0.1 mL), vancomycin (1 mg/0.1 mL) and voriconazole (100 µg/0.1 mL). After 2 days of topical steroid treatment, the patient was started on oral Prednisolone 1 mg/kg/day with weekly tapering. An improvement with this initial treatment was noted in the form of gradual reduction and disappearance of hypopyon and retraction of the inflammatory membrane. There was minimal improvement in the fundal glow and the USG examination showed significant reduction in the number and intensity of the echoes but there was no improvement in the VA of the patient. No organism was isolated on preliminary vitreous biopsy. Based on the clinical improvement, the initial treatment of subconjunctival and intravitreal injections was repeated twice in the same dose as previously given.

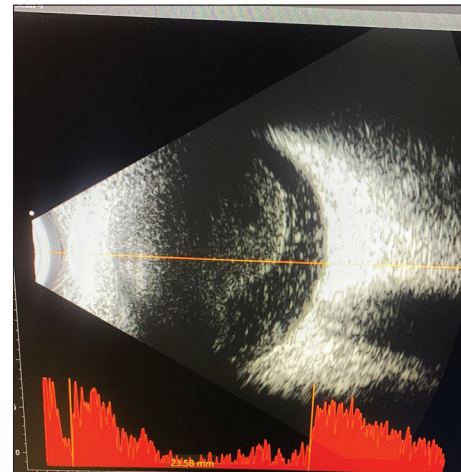
A myriad of systemic investigations was also performed to identify the source of infection. Apart from a complete blood count with peripheral smear for malarial parasite, a blood culture, USG of abdomen and pelvis, chest and sacroiliac joint X rays and a complete uveitic profile including anti streptolysin O, C-reactive protein, rheumatoid arthritis factor, erythrocytes sedimentation rate (ESR) and rapid plasma reagin for syphilis were done, none of which were particularly conclusive except for elevated levels of ESR (>65 mm). No organisms were isolated in any of the subsequent vitreous biopsy samples.

By the 10<sup>th</sup> day, the patient had minimal AC reaction with no hypopyon, a paper thin inflammatory membrane overlying 1 mm central zone of the crystalline lens and an organised posterior segment inflammation with high intensity echoes persistently in the anterior and posterior vitreous cavity on B scan USG. No further improvement was noted for the next 4 days with the same treatment. The patient was advised for pars plana vitrectomy. Following this, the VA in LE improved to 6/60 with pinhole with significant improvement in the clarity of anterior and posterior segments [Figure 3].

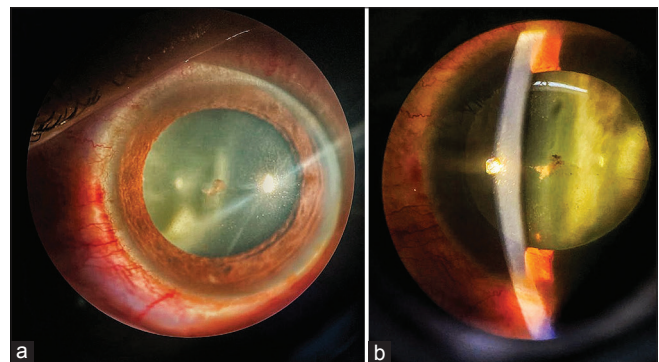
In the meantime, USG of both kidneys was performed for the flank pain that revealed the presence of the right-sided ureteric stone (measuring 6 mm in diameter) with obstructive uropathy and pyelonephritis for which he then underwent right-sided double J stenting. A urine culture showed presence of Gram-positive lactose fermenting bacilli, not isolated on any of the previous blood or urine cultures or vitreous biopsies, for which he was started on injection of Meropenem 500 mg twice a day for 7 days. The patient is



**Figure 1:** Slit lamp examination picture on diffuse illumination on presentation showing 1 mm hypopyon in the anterior chamber.



**Figure 2:** Ultrasound B Scan of Left Eye showing moderate to high intensity vitreous echoes in anterior and mid vitreous cavity.



**Figure 3:** (a) Diffuse illumination on slit lamp at 6 weeks show quiet anterior chamber with small central retracted inflammatory membrane. (b) Optical section showing clear cornea with minimal anterior chamber inflammation.

under follow-up and gradually improving. At the last follow-up visit, the VA improved to 6/24 BCVA on the Snellen distant acuity chart.

## DISCUSSION

EE refers to the infection of the intraocular cavities resulting from a haematogenous dissemination of pathogens to the eye.<sup>[2]</sup> These pathogens typically reach the choroid or retina and then cross the blood retinal barrier to infect the vitreous cavity.<sup>[5]</sup> EE is relatively rare and has been shown to account for 2–8% of all endophthalmitis cases in different studies.<sup>[1]</sup> It is most often associated with a diagnosed underlying medical condition such as diabetes mellitus, liver disease, cardiac disease, malignancy, in-dwelling catheters, and IV drug abuse (IVDU).<sup>[6]</sup>

The previous studies, primarily from Asia, found that liver abscess was the most common infective source in their cohorts with *Klebsiella pneumoniae* being the most frequent causative organism.<sup>[7,8]</sup> Zhang and Wang demonstrated a 63% fungal aetiology in their series of EE.<sup>[7]</sup> The varied spectrum of microbial isolates and the associated risk factors most likely reflect the geographical location of the studies and the patient case-mix presented to the various institutions. In Connell *et al.* study group, the increased numbers of fungal EE cases (65.9% of all culture-positive cases) were causally linked with a history of IVDU and resulted in a statewide public health campaign aimed at reducing the incidence of this condition in this group.<sup>[9,10]</sup> In our case, it is suspected to have disseminated from an endogenous renal foci of infection. Due to the dry and scarce nature of the vitreous biopsy specimen, the presence of the pathogen was not culpable in the vitreous cavity which prompted the need for an extensive systemic workup backed by a thorough history to help elucidate the presence of a systemic cause of inflammation. The general prognosis in EE is poor and guarded unless rapid isolation of the organism intraocularly is established through various diagnostic modalities and a targeted therapy is initiated. A delay in any of these can lead to further dissemination of the inflammation to various structures of the eye and consequent blindness. The obvious haematogenous spread of the organism can involve other tissues and organs as well leading to systemic morbidity and mortality.

## CONCLUSION

EE is a vision threatening condition disseminated from a foci of infection located and originating elsewhere in the body. It is prudent to perform a plethora of systemic investigations keeping in mind the importance of a detailed history and general and thorough examination to clinically as well as microbiologically rule out the presence

of an infective foci and initiate timely and specific treatment.

## Declaration of patient consent

The authors certify that they have obtained all appropriate patient consent.

## Financial support and sponsorship

Nil.

## Conflicts of interest

There are no conflicts of interest.

## REFERENCES

1. Jackson TL, Paraskevopoulos T, Georgalas I. Systematic review of 342 cases of endogenous bacterial endophthalmitis. *Surv Ophthalmol* 2014;59:627-35.
2. Sadiq MA, Hassan M, Agarwal A, Sarwar S, Toufeeq S, Soliman MK, *et al.* Endogenous endophthalmitis: Diagnosis, management and prognosis. *J Ophthalmic Inflamm Infect* 2015;5:32.
3. Dadia SD, Modi RR, Shirwadkar S, Potdar NA, Shinde CA, Nair AG. *Salmonella* Typhi associated endogenous endophthalmitis: A Case report and a review of literature. *Ocul Immunol Inflamm* 2018;26:527-32.
4. Lin HH, Chien CC, Fang JT, Lai RH, Huang CC. Unusual clinical presentation of *Klebsiella pneumoniae* induced endogenous endophthalmitis and xanthogranulomatous pyelonephritis in a non-nephrolithiasis and non-obstructive urinary tract. *Ren Fail* 2002;24:659-65.
5. Chee SP, Jap A. Endogenous endophthalmitis. *Curr Opin Ophthalmol* 2001;12:464-70.
6. Okada AA, Johnson RP, Liles WC, D'Amico DJ, Baker AS. Endogenous bacterial endophthalmitis. Report of a ten-year retrospective study. *Ophthalmology* 1994;101:832-8.
7. Zhang YQ, Wang WJ. Treatment outcomes after pars plana vitrectomy for endogenous endophthalmitis. *Retina* 2005;25:746-50.
8. Yoon YH, Lee SU, Sohn JH, Lee SE. Result of early vitrectomy for endogenous *Klebsiella pneumoniae* endophthalmitis. *Retina* 2003;23:366-70.
9. Aboltins CA, Allen P, Daffy JR. Fungal endophthalmitis in intravenous drug users injecting buprenorphine contaminated with oral *Candida* species. *Med J Aust* 2005;182:427.
10. Connell PP, O'Neill EC, Fabinyi D, Islam FM, BATTERY R, McCombe M, *et al.* Endogenous endophthalmitis: 10-year experience at a tertiary referral centre. *Eye (Lond)* 2011;25:66-72.

**How to cite this article:** Shah SM, Suthar DN, Mehta KS, Bhagat PR. A rare case of pyelonephritis-associated endogenous endophthalmitis. *Glob J Cataract Surg Res Ophthalmol* 2023;2:9-11.