

Case Report

Persistent oozing: Are we overlooking something?

Megha Rashmikant Brahmhatt¹, Purvi Raj Bhagat¹ 

¹Department of Ophthalmology, Maneklal and Jagiivan Ujamshi, Western Regional Institute of Ophthalmology, Byramjee and Jeejeebhoy Medical College, Ahmedabad, Gujarat, India.

ABSTRACT

This report highlights two cases of undiagnosed haemorrhagic disorders presenting with excessive bleeding during or after routine ocular procedures. Case 1 involved a 50-year-old male with intraoperative bleeding during cataract surgery, later diagnosed with aplastic anaemia. Case 2, a 31-year-old male, experienced post-operative bleeding after chalazion excision, with haematological tests revealing haemophilia. Both patients required specialised treatment, including haematology consultation and specific factor replacement therapy. These cases emphasise the importance of high suspicion and early recognition of underlying coagulation disorders in cases of uncontrolled ocular bleeding which can be a crucial indicator of such conditions.

Keywords: Aplastic anaemia, Bleeding, Haemophilia, Ocular surgery

INTRODUCTION

For a minor procedure like cataract surgery, the specific laboratory or other tests required are unclear. Most cataracts are performed on older individuals with some or other systemic and ocular comorbidities. It is likely that routine pre-operative medical testing will detect medical conditions, but it is questionable whether these conditions should preclude individuals from cataract surgery or change their perioperative management. Given the high and growing number of cataract and other elective surgeries in ophthalmology, it is essential to enhance both safety and cost-efficiency of this procedure.^[1] Different guidelines suggest different assessments and investigations.

Pre-operative laboratory testing is an integral part of any elective ophthalmic surgery. Routine tests such as complete blood counts (CBCs), blood pressure, blood sugar levels, urine analysis and reactive status typically reveal most undiagnosed systemic conditions that need addressing before surgery.^[2] For patients with risk factors or those requiring general anaesthesia, more specific tests such as electrocardiogram, chest X-ray, kidney function tests and appropriate referrals may be necessary.

Only few reports exist that detail a diagnosis of haemophilia following ophthalmic surgery. Iyengar *et al.* documented

a case in which a congenital cataract extraction led to the diagnosis of Factor XI deficiency in a 4-month-old boy.^[3] Similarly, a case reported by Aquino *et al.* identified haemophilia as the cause of recurrent ocular haemorrhage in an 8-year-old boy who experienced blunt trauma to his right eye.^[4]

Ocular bleeding in patients with bleeding diathesis is often overlooked or treated routinely unsuspecting of any systemic disorder; however it can have serious implications. If the bleeding is more severe than what would be expected, it should signal a more serious underlying issue warranting further investigation. Here, we present two such unusual cases where a bleeding disorder was first considered only after excessive bleeding occurred during an attempted surgery.

CASE REPORT

Case 1

A 50-year-old male presented to our tertiary care centre with complaints of progressive diminution of vision in both eyes since 6 months. No history of ocular trauma, systemic illness or bleeding diathesis was given. On examination, patient's visual acuity was (Oculus Dexter [OD]): Hand movements present (+), perception of light present (+), projection of rays

*Corresponding author: Megha Rashmikant Brahmhatt, Department of Ophthalmology, Maneklal and Jagiivan Western Regional Institute of Ophthalmology, Byramjee and Jeejeebhoy Medical College, Ahmedabad, Gujarat, India. megha1608@icloud.com

Received: 13 February 2025 Accepted: 03 March 2025 Epub Ahead of Print: 18 April 2025 Published: XXXXXX DOI: 10.25259/GJCSRO_6_2025

This is an open-access article distributed under the terms of the Creative Commons Attribution-Non Commercial-Share Alike 4.0 License, which allows others to remix, transform, and build upon the work non-commercially, as long as the author is credited and the new creations are licensed under the identical terms. ©2025 Published by Scientific Scholar on behalf of Global Journal of Cataract Surgery and Research in Ophthalmology

present in all 4 quadrants (4+) (HM+PL+PR4+) (Oculus Sinister [OS]): 6/6. The anterior segment was within normal limits. Lens examination revealed: (OD) mature cataract; (OS) pseudophakia. Ultrasonography of the right eye was normal. The left eye fundus was normal. Pre-operative CBC and other routine tests (blood sugar, urine analysis and viral markers) were performed, revealing no significant abnormalities.

The patient was scheduled for a (OD) small incision cataract extraction surgery with a posterior chamber intraocular lens under local anaesthesia. During the surgery, excessive bleeding occurred in the anterior chamber while creating the scleral tunnel wound, resulting in obscured visibility and ultimately leading to the abandonment of the surgery. The incision was sutured immediately and the eye was patched tightly. The patient was advised Tablet Acetazolamide 500 mg and Tablet Vitamin C 500 mg to be taken twice a day along with a potassium supplement. On the first post-operative day, the patient had full chamber hyphaema with blood clots. Rest details were not visualised. The B-scan was within normal limits. The patient was advised moxifloxacin 0.5% eye drops *Quater Die Sumendum* (QDS), prednisolone 1% eye drops 1 hourly and atropine sulphate 1% eye ointment *Ter Die Sumendum* (TDS).

To eliminate the possibility of any haematological abnormalities, a repeat peripheral smear was conducted, which then revealed low platelet counts. A consultation with a haematologist was performed leading to a diagnosis of aplastic anaemia. The patient was then started on Eltrombopag tablets at a dosage of 100 mg OD, along with Prednisolone tablets at a dosage of 25 mg BD.

Case 2

A 31-year-old male patient presented with sudden onset upper eyelid bleeding following a chalazion excision in the left eye performed elsewhere 3 days ago, with no history of ocular trauma. His visual acuity, as measured on the Snellen chart, was (OU) 6/6. On examination, cauterisation marks were present over the upper palpebral conjunctiva of the left eye with an ill-defined source of bleeding [Figure 1a-c]. Rest of the anterior and posterior segment were found to be unremarkable.

A compressive dressing was applied to control the bleeding. Blood analysis revealed an abnormal coagulation profile: normal prothrombin time and International Normalised Ratio, but an altered activated partial thromboplastin time of 48 sec with low Factor 8 (25%) and high Factor 9 (20 unit/dL). The patient was referred to a haematologist and diagnosed with Haemophilia A. Treatment was initiated with an intravenous injection of Factor 8 (1500 IU stat), an intravenous injection of Tranexamic acid (1 g stat) and Etamsylate tablets (500 mg 6 hourly for 2 days). The bleeding stopped on the same day. The patient continued regular follow-up until complete healing occurred [Figure 2a-c].

DISCUSSION

Most guidelines suggest routine blood investigations, including CBC, urine routine and microbiology, random blood sugar, serum creatinine and viral markers for hepatitis B, C and human immunodeficiency virus, along with blood pressure measurements for all ophthalmic pre-operative patients. More than half of the population visiting a government hospital is often unaware of any underlying

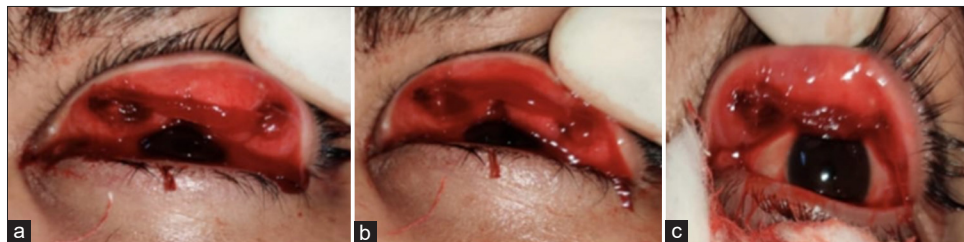


Figure 1: (a-c) A 31-year-old male patient with ill-defined upper palpebral conjunctival bleeding and cauterisation marks.

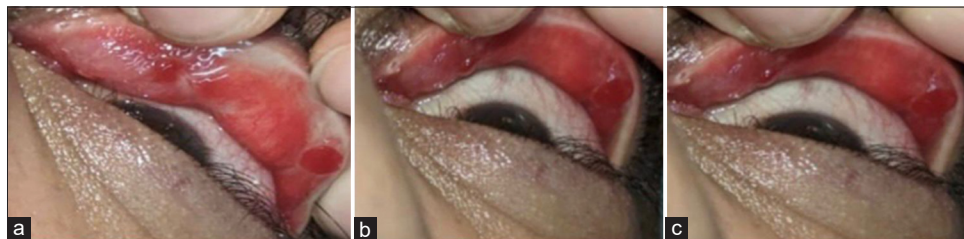


Figure 2: (a-c) A 31-year-old male patient after the cessation of bleeding, following treatment with Factor VIII and other haemostatic agents.

comorbidities. Approximately 40 to 50 percentages are diagnosed with hypertension or uncontrolled diabetes mellitus just preoperatively. However, bleeding disorders are not routinely investigated leading to missed diagnosis. In a litigious society, physicians generally believe that being more cautious and conducting additional tests is a safer approach in court.^[5]

Few reports have documented the outcomes of ocular surgeries in patients with haemophilia. In a study by Fabian *et al.*, a series of seven known haemophilic patients underwent elective phacoemulsification without prior factor correction.^[6] The surgeries were uneventful. A 2001 case series by Jijina *et al.* described five haemophilic patients who underwent surgery, including two boys with traumatic hyphaemas resulting from blunt ocular trauma.^[7] One patient with severe haemophilia had an uneventful recovery after receiving factor transfusion pre-operatively. The other, undiagnosed with moderate haemophilia B, experienced rebleeding and vitreous haemorrhage post-surgery. After factor correction and medical treatment, his vision improved. Similarly, cases published by Jiang *et al.*^[8] and Chan *et al.*^[9] have reported retinal and subhyaloid haemorrhage in patients of aplastic anaemia leading to severe visual impairment.

Complications during surgery in patients with bleeding disorders can arise especially if it is often undiagnosed before the procedure. If any unexpected or unusual complications arise during any surgery, it is crucial to keep a strong eye for suspicion for other potential systemic issues. Prompt referrals to specialists and a multidisciplinary approach, along with close post-operative monitoring, are vital for achieving the best outcomes. Each case should be considered individually, with decisions about whether or not to proceed with surgery based on the patient's specific circumstances.

CONCLUSION

Uncontrolled non-traumatic spontaneous ocular bleeding can reveal underlying coagulation disorders. Unexpected surgical complications warrant further evaluation and often a multidisciplinary management.

Ethical approval: Institutional Review Board approval is not required.

Declaration of patient consent: The authors certify that they have obtained all appropriate patient consent.

Financial support and sponsorship: Nil.

Conflicts of interest: Dr Purvi Raj Bhagat is on the editorial board of the Journal.

Use of artificial intelligence (AI)-assisted technology for manuscript preparation: The authors confirm that there was no use of artificial intelligence (AI)-assisted technology for assisting in the writing or editing of the manuscript and no images were manipulated using AI.

REFERENCES

1. Keay L, Lindsley K, Tielsch J, Katz J, Schein O. Routine preoperative medical testing for cataract surgery. *Cochrane Database Syst Rev* 2019;1:CD007293.
2. Available from: https://npcbvi.mohfw.gov.in/Documents/Guidelines/1978_Camp_Guidelines.pdf [Last accessed on 2025 Feb 10].
3. Iyengar SS, Olitsky SE, Neville KA. Diagnosis of factor XI deficiency following congenital cataract extraction. *J AAPOS* 2008;12:297-8.
4. Aquino LM, Ranche FK. Hemophilia presenting as recurrent ocular hemorrhage. *GMS Ophthalmol Cases* 2020;10:Doc15.
5. Sirovich BE, Woloshin S, Schwartz LM. Too little? Too much? Primary care physicians' views on US health care: A brief report. *Arch Intern Med* 2011;171:1582-5.
6. Fabian ID, Sachs D, Moisseiev J, Alhalel A, Grinbaum A, Seligsohn U, *et al.* Cataract extraction without prophylactic treatment in patients with severe factor XI deficiency. *Am J Ophthalmol* 2009;148:920-4.e1.
7. Jijina F, Ghosh K, Madkaikar M, Mohanty D. Ophthalmic surgery in haemophilia. *Haemophilia* 2001;7:464-7.
8. Jiang X, Shen M, Liang L, Rosenfeld PJ, Lu F. Severe retinal hemorrhages at various levels with a serous retinal detachment in a pediatric patient with aplastic anemia-a case report. *Front Med* 2023;10:1051089.
9. Chan WM, Liu DT, Tham CC, Wu RM, Lam DS. Bilateral subhyaloid haemorrhage in aplastic anaemia. *Br J Haematol* 2003;123:757.

How to cite this article: Brahmbhatt MR, Bhagat PR. Persistent Oozing: Are we overlooking something? *Glob J Cataract Surg Res Ophthalmol*. doi: 10.25259/GJCSRO_6_2025