

Innovation

# Utilisation of trypan blue dye as a diagnostic tool during cataract surgery in patients suspected to have pseudoexfoliation syndrome

Tiffany N. Lien<sup>1</sup>, Helio Vinicius Neves da Silva<sup>1</sup>, Cristos Ifantides<sup>2,3</sup>

<sup>1</sup>University of Colorado School of Medicine, <sup>2</sup>Department of Ophthalmology, University of Colorado College of Medicine, Aurora, Colorado, <sup>3</sup>Tyson Eye, Cape Coral, Florida, United States.

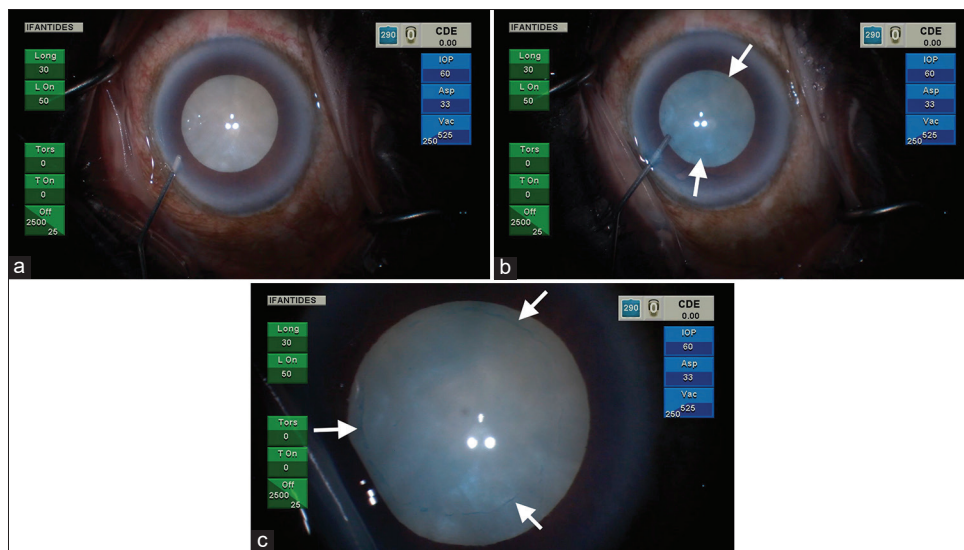
## ABSTRACT

Pseudoexfoliation syndrome (PEX) is diagnosed clinically by slit-lamp examination, but classic examination findings can be subtle or absent in the early disease. Trypan blue dye can be used as a diagnostic tool during cataract surgery in patients suspected to have PEX.

**Keywords:** Pseudoexfoliation syndrome, Trypan blue, Cataract surgery, Glaucoma, Capsule

Pseudoexfoliation syndrome (PEX) is a systemic syndrome that manifests most prominently in the anterior segment of the eye, characterized by dandruff-like deposits of extracellular matrix material on the anterior lens capsule, iris, corneal epithelium, ciliary body, and zonules. Over

time, the abrasive movement of the iris against the lens gives rise to the classic central disc and peripheral ring of white deposits on the anterior capsule and flaky material dispersed throughout the anterior chamber. Important clinical manifestations of PEX include increased risk of

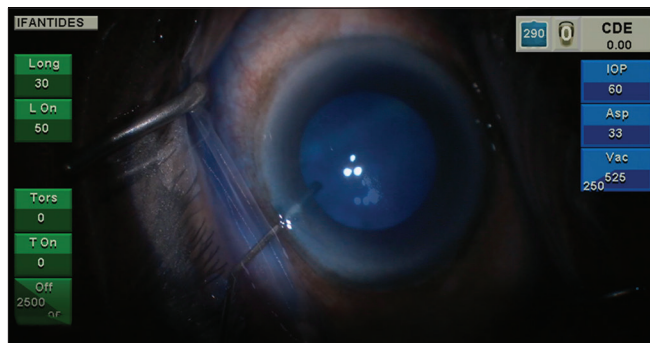


**Figure 1:** (a) Photo showing a white cataract. (b) Photo showing the white cataract now stained with trypan blue. Notice the outlined pseudoexfoliation material (white arrows). (c) Zoomed in photo showing the white cataract stained with trypan blue. Notice the outlined pseudoexfoliation material (white arrows).

\*Corresponding author: Cristos Ifantides, Department of Ophthalmology, University of Colorado College of Medicine, Aurora, Colorado, United States. [cristosmd@gmail.com](mailto:cristosmd@gmail.com)

Received: 06 December 2022 Accepted: 08 January 2023 Published: 24 February 2023 DOI: 10.25259/GJCSRO\_27\_2022 Videos available on: <https://www.gjcsro.com>

This is an open-access article distributed under the terms of the Creative Commons Attribution-Non Commercial-Share Alike 4.0 License, which allows others to remix, transform, and build upon the work non-commercially, as long as the author is credited and the new creations are licensed under the identical terms. ©2022 Published by Scientific Scholar on behalf of Global Journal of Cataract Surgery and Research in Ophthalmology



**Video 1:** Video showing utilization of trypan blue in patient without obvious pseudoexfoliation.

intraoperative complications during cataract surgery and elevated intraocular pressure, which can lead to pseudoexfoliative glaucoma, due to the blockage of the trabecular meshwork by PEX material. Here we describe a method of intraoperative diagnosis in patients with undiagnosed PEX due to a white cataract.

A 64-year-old woman presented to Denver Health Medical Centre for cataract surgery. Her ophthalmic history was limited to pseudophakia in her left eye, done outside of our hospital system. Pre-operative assessment with slit-lamp biomicroscopy showed an intraocular lens in her left eye and a dense white cataract in the right eye with no view to the right posterior pole [Figure 1a]. During the surgery, Trypan blue dye (TB) was used due to poor red reflex visibility. After the dye was washed out, a peripheral ring of pseudoexfoliative material stained by the dye is clearly visible, revealing a diagnosis of pseudoexfoliation syndrome (PEX) [Figures 1b and c]. See [Video 1] for full sequence.

PEX is diagnosed clinically by direct visualisation of pseudoexfoliative deposits on slit-lamp examination with pupillary dilation and gonioscopy. However, many cases do not present with unequivocal signs of PEX as classic examination findings may be absent early on or visualisation may be poor due to inadequate mydriasis. PEX deposits are composed of basement membrane material, which is selectively stained by TB. TB has been shown to stain more strongly in PEX patients, because it stains the pseudoexfoliative material in addition to the basement membrane of the anterior lens capsule. We recommend consideration of TB as a diagnostic tool in PEX suspects and populations at high risk for PEX undergoing cataract surgery. An intraoperative diagnosis can help prevent the known surgical complications associated with PEX and lead to improved surgical outcomes and can help properly diagnose PEX glaucoma which can be misdiagnosed as primary open-angle glaucoma.

#### Declaration of patient consent

Patient's consent not required as patients identity is not disclosed or compromised.

#### Financial Support and Sponsorship

Nil.

#### Conflicts of Interest

There are no conflicts of interest.

**How to cite this article:** Lien TN, Da Silva HV, Ifantides C. Utilisation of trypan blue dye as a diagnostic tool during cataract surgery in patients suspected to have pseudoexfoliation syndrome. *Glob J Cataract Surg Res Ophthalmol* 2022;1:105-6.