

Case Report

# A rare presentation of saccular aneurysm at junction of middle carotid artery and internal carotid artery mimicking the normal tension glaucoma

Dipika Govindbhai Mahakal<sup>1</sup>, Aavisha Vikash Shah<sup>1</sup>, Kamini M. Prajapati<sup>1</sup>, Purvi Raj Bhagat<sup>1</sup>

<sup>1</sup>Department of Ophthalmology, M & J Western Regional Institute of Ophthalmology, Ahmedabad, Gujarat, India.

## ABSTRACT

Acquired (pathologic) excavation of the optic cup is not always due to glaucoma. Ophthalmological signs of pathological disc cupping have been recognised in patients with normal intraocular pressures and with optic atrophy of various causes including ischaemic and compressive optic neuropathy, optic neuritis and trauma. Intracranial lesions have been reported to mimic the clinical presentation of glaucomatous optic disc changes and have also resulted in misdiagnosis. Optic atrophy caused by intracranial lesions shows pallor more than cupping. The macular nasal-temporal ratio compares the nasal and temporal thickness of the macular ganglion cell and inner plexiform layer and can be used to differentiate between compressive and non-compressive lesions as depicted in this case. This case report also suggests the importance of different imaging modalities in diagnosing compressive lesions and differentiating them from similar conditions.

**Keywords:** Intraocular pressure, Optic cup, Glaucoma, Neuro-ophthalmology, Neuroimaging modalities

## INTRODUCTION

Intracranial lesions have been reported to mimic the clinical presentation of glaucomatous optic disc changes and have also resulted in misdiagnosis. Differentiation between glaucomatous and non-glaucomatous optic neuropathies is both clinically and economically relevant. The incorrect diagnosis of neuro-ophthalmological conditions can not only lead to unnecessary treatment with topical hypotensive drugs but also a deep psychological impact of a lifelong treatment to the patient and consequences of missing serious scenarios such as treatable intracranial tumours.<sup>[1]</sup> This case report aims to indicate the importance of imaging modalities to diagnose and differentiate between such mimicking conditions.

## CASE REPORT

A 51-year-old female patient initially presented in 2020 for a routine ophthalmological checkup in the outdoor patient department (OPD) of our tertiary care centre. In the right eye (RE), the vision was 6/9 with -0.5 D spherical and in the left eye (LE), the vision was 6/6 with -1.00 D cylindrical at 90°. She has been prescribed glasses for the same and

a yearly follow-up was given. Then, the patient presented in our OPD in June 2022 with complaints of headache and ocular pain for 1 month for which the patient consulted at a nearby eye hospital, and then, the patient was referred to a tertiary eye care hospital for glaucoma assessment. On detailed evaluation, the patient complained of blurring of vision in the RE and frontal headache which was on and off, throbbing in nature and relieved by analgesic medications. The patient had no history of trauma, seizure, vomiting, or coloured halos. There is no history of COVID-19 infection, any ocular surgery, significant drug history or significant family history. The patient has had a known case of hypertension for 5 years and taking a tablet of amlodipine 5 mg as per prescription. General physical examination was unremarkable. On examination, visual acuity in RE was 6/9 and in LE 6/6 with glasses. On slit-lamp examination, RE showed developmental scattered lenticular opacities and LE anterior segment was within normal limits. Central corneal thickness was 520 µm and 526 µm in both eyes, respectively, using an ultrasonic pachymeter. Intraocular pressure taken by Goldmann Applanation tonometer was 12 mmHg in RE and 14 mmHg in LE. On gonioscopy, both eyes showed open

\*Corresponding author: Dipika Govindbhai Mahakal, Department of Ophthalmology, M & J Western Regional Institute of Ophthalmology, Ahmedabad, Gujarat, India. [dipikamahakal1510@gmail.com](mailto:dipikamahakal1510@gmail.com)

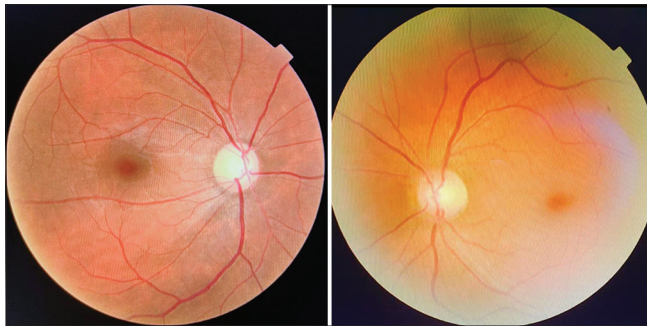
Received: 15 April 2024 Accepted: 26 May 2024 Epub Ahead of Print: 24 July 2024 Published: 07 January 2025 DOI: 10.25259/GJCSRO\_17\_2024

This is an open-access article distributed under the terms of the Creative Commons Attribution-Non Commercial-Share Alike 4.0 License, which allows others to remix, transform, and build upon the work non-commercially, as long as the author is credited and the new creations are licensed under the identical terms. ©2024 Published by Scientific Scholar on behalf of Global Journal of Cataract Surgery and Research in Ophthalmology

angles according to Schaffer's grading. Fundus examination [Figure 1] shows 0.4 – 0.5 cup-to-disc ratio (CDR) in RE with shallow cupping and temporal pallor and 0.5 – 0.6 CDR in LE with shallow cupping and temporal pallor with no retinal nerve fibre layer (RNFL) defect was found. A diurnal variation test was done which was within normal range. Blood pressure was 126/84 mmHg in the supine position. RNFL optical coherence tomography [Figure 2a] showed temporal loss of ganglion cells and temporal thinning of RNFL in both eyes. The ganglion cell map [Figure 2b] was suggestive of RE 360° thinning and LE temporal thinning. Perimetry [Figures 3 and 4] was done before neurological surgical intervention at 6-month intervals by Octopus 900 perimeter, using the G standard program, tendency oriented perimetry strategy showed vertically aligned central and paracentral scotoma in both the eyes. Perimetry [Figure 4] was done after a 6-month

interval of the first visual field report suggestive of worsening of the visual field. On the neurological visual field [Figure 5], vertically aligned hemianopic relative defect in both eyes was found.

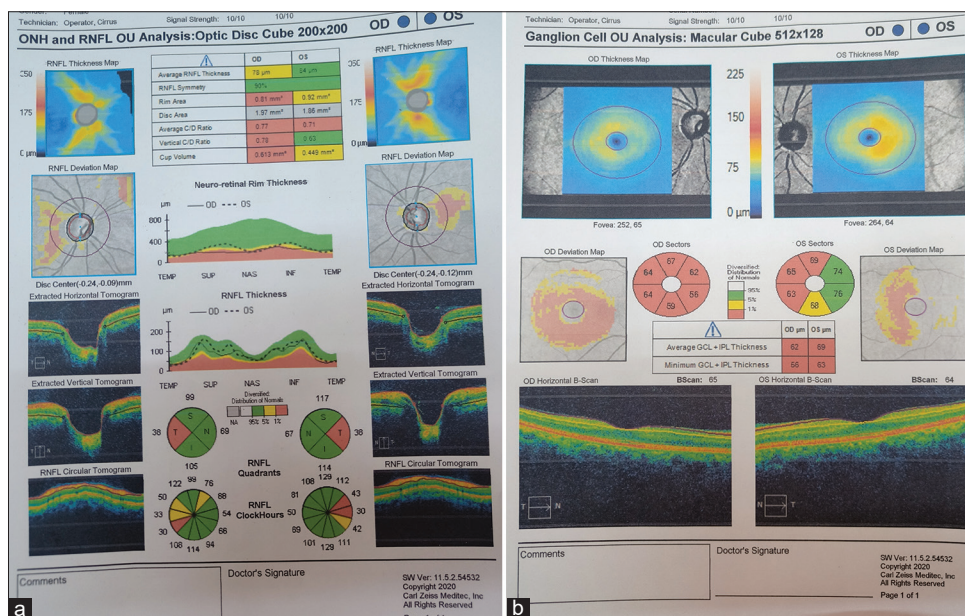
The patient was advised to do a 1.5 T magnetic resonance imaging (MRI) of the brain with orbit and angiography. On MRI [Figure 6], a 16 × 16 × 16 mm saccular aneurysm involving the junction of the terminal segment of the right internal carotid artery (ICA) and right middle carotid artery with an abutment, compression, displacement of the right optic nerve and optic chiasma and infundibulum was found. The patient was referred to a neurosurgeon. A flow diverter stent endovascular reconstruction procedure with partial coil embolisation for the right ICA superior hypophyseal wide neck aneurysm under general anaesthesia was done by the neurosurgeon, and then, the patient was relieved from the headache and periocular pain. In the post-operative period, she was prescribed antihypertensive, antiplatelets and blood thinner oral medication. At present, she is using tablet amlodipine 5 mg once a day and tablet aspirin 75 mg once a day.



**Figure 1:** Fundus photographs showing 0.4 – 0.5 cup-to-disc ratio (CDR) with temporal pallor in the right eye and 0.5 – 0.6 CDR with temporal pallor in the left eye.

### DISCUSSION


This case report supports the view of intracranial compressive lesions that must be considered in the workup of patients with complaints of headache, giddiness, blurring of vision, and/or periocular pain. The most common lesions to consider include aneurysms, gliomas, meningiomas, craniopharyngiomas, pituitary tumour cysts, and chordomas affecting pre-chiasmal and/or chiasmal visual pathways. These lesions may increase



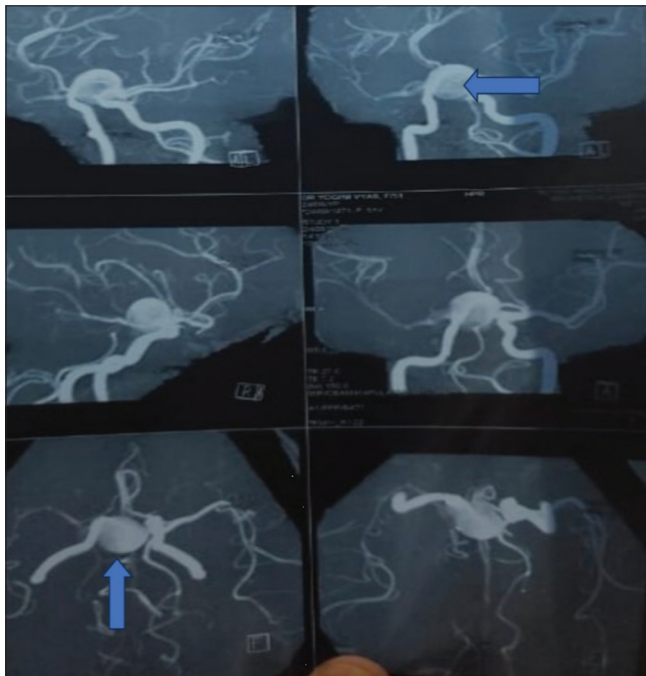
**Figure 2:** (a) Retinal nerve fibre layer (RNFL) optical coherence tomography showing temporal neuroretinal rim thinning and RNFL thinning in both eyes. (b) Ganglion cell map showing 360° thinning in the right eye and nasal thinning in the left eye.







**Figure 5:** Neurological visual field report of this patient showing vertically aligned hemianopic relative defects in both eyes.



**Figure 6:** Magnetic resonance imaging brain with angiography showing the saccular aneurysm (blue arrow) at the junction of middle carotid artery and internal carotid artery.

## CONCLUSION

We must take an interdisciplinary approach and take help of other diagnostic imaging modalities for confirmation of diagnosis and accurate management.

## Ethical approval

Institutional Review Board approval is not required.

## Declaration of patient consent

The authors certify that they have obtained all appropriate patient consent.

## Financial support and sponsorship

Nil.

## Conflicts of interest

Dr. Purvi Raj Bhagat and Dr. Kamini M. Prajapati are on the editorial board of the Journal.

## Use of artificial intelligence (AI)-assisted technology for manuscript preparation

The authors confirm that there was no use of artificial intelligence (AI)-assisted technology for assisting in the writing or editing of the manuscript and no images were manipulated using AI.

## REFERENCES

1. Fraser CL, White AJ, Plant GT, Martin KR. Optic nerve cupping and the neuro-ophthalmologist. *J Neuroophthalmol* 2013;33:377-89.
2. Kosior-Jarecka E, Wrobel-Dudzińska D, Pietra R, Pankowska A, Szczuka B, Żarnowska I, *et al.* Results of neuroimaging in patients with atypical normal-tension glaucoma. *Biomed Res Int* 2020;2020:9093206.
3. Trobe JD, Glaser JS, Cassady JC, Herschler J, Anderson DR. No glaucomatous excavation of the optic disc. *Arch Ophthalmol* 1980;98:1046-50.
4. Dias DT, Uchida M, Battistella R, Dorairaj S, Prata TS. Neuroophthalmological conditions mimicking glaucomatous optic neuropathy: Analysis of the most common causes of misdiagnosis. *BMC Ophthalmol* 2017;17:2.
5. Park JW, Jung HH, Heo H, Park SW. Validity of the temporal-to-nasal macular ganglion cell-inner plexiform layer thickness ratio as a diagnostic parameter in early glaucoma. *Acta Ophthalmol* 2015;93:e356-65.

**How to cite this article:** Mahakal DG, Shah AV, Prajapati KM, Bhagat PR. A rare presentation of saccular aneurysm at junction of middle carotid artery and internal carotid artery mimicking the normal tension glaucoma. *Glob J Cataract Surg Res Ophthalmol.* 2024;3:122-5. doi: 10.25259/GJCSRO\_17\_2024