

## Case Report

# Custard apple seeds induced toxic keratoconjunctivitis

Payal Gonde (Ballamwar)<sup>1</sup>

<sup>1</sup>Department of Ophthalmology, Vasan Eye Care, Secunderabad, Telangana, India.

## ABSTRACT

The patient developed severe symptoms of toxic keratoconjunctivitis within 6-12 h following accidental ocular exposure to custard apple seeds (*Annona squamosa*) which are used as a remedy for lice/dandruff in some parts of India. A 12 year-old female child was diagnosed with custard apple seed-induced toxic keratoconjunctivitis. A patient with informed consent was enrolled. She was advised to use topical antibiotics, lubricating agents and cycloplegic eye drops. She responded well to treatment and keratoconjunctivitis resolved in 3 weeks with complete restoration of vision in both eyes. This case highlights the importance of prevailing traditional practices. Simple health education and more public awareness of harmful effects of custard apple seeds should be created to prevent such chemical injury.

**Keywords:** Custard apple seeds, *Annona squamosa*, Keratitis, Harmful traditional practice, Keratoconjunctivitis

## INTRODUCTION

Due to its sweet taste, the edible tropical fruit known as the custard apple (*Annona squamosa* L.) is additionally known as the sugar apple. The custard apple is a fruit of the *A. squamosa* or *Annona asiatica* plant, which is a member of the *Annona* genus and *Annonaceae* family<sup>[1]</sup> [Figure 1]. It contains active compounds such as alkaloids-cyclohexapeptides and acetogenins (ACGs).<sup>[2]</sup> It is produced throughout India. Injurious traditional folk medicine uses various components of this plant to cure a variety of ailments, including boils, ulcers, maggot-infested wounds, head lice and skin exfoliation.<sup>[3]</sup> In some regions of South India, it is common for them to come into contact with the eyes accidentally, particularly when they are used as a traditional treatment for dandruff and lice infestations of the scalp or as a skin exfoliator for the face. Studies on the *A. squamosa* seed's phytochemistry and pharmacology have revealed that the main bioactive substances are ACGs.<sup>[2]</sup> Here is a case report wherein the patient developed custard apple seed-induced keratoconjunctivitis following accidental ocular exposure to it.

## Mechanism of action

Annosquacins A to D (1-4), annosquatin A (5) and annosquatin B (6) were discovered through phytochemical analysis of the ethanol fraction of custard apple seeds. ACGs

have a wide range of biological characteristics, including anti-inflammatory, cytotoxic, immunosuppressive, pesticidal, antiparasitic and antibacterial effects.<sup>[4]</sup> The isolation of eight cytotoxic acetogenins from the seeds of *A. squamosa*.<sup>[5]</sup> It has a wide range of nutritional benefits and numerous health advantages for individuals.<sup>[6]</sup> Research studies on the mechanisms of action revealed that the mitochondrial respiratory chain complex I (Nicotinamide adenine dinucleotide: Ubiquinone oxidoreductase), one of the respiratory complexes that produce the proton-motive force needed for the production of Adenosine triphosphate (ATP) in mitochondria, is the most effectively inhibited by ACGs.<sup>[7]</sup>



Figure 1: Custard apple.


\*Corresponding author: Payal Gonde (Ballamwar), Department of Ophthalmology, Vasan Eye Care, Secunderabad, Telangana, India. [payalgonde@gmail.com](mailto:payalgonde@gmail.com)

Received: 04 July 2023; Accepted: 30 July 2023; EPub Ahead of Print: 09 October 2023 Published: 07 January 2025 DOI: 10.25259/GJCSRO\_14\_2023

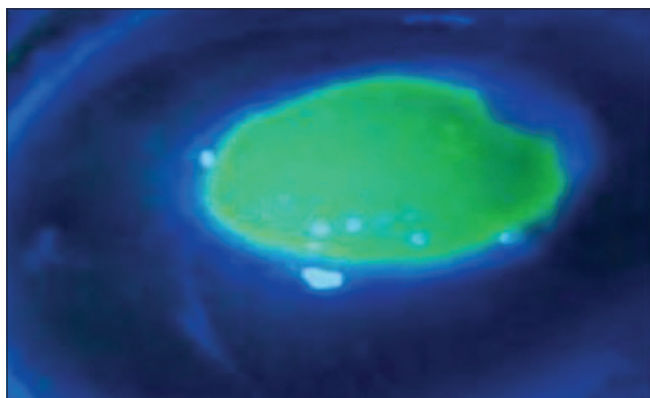
This is an open-access article distributed under the terms of the Creative Commons Attribution-Non Commercial-Share Alike 4.0 License, which allows others to remix, transform, and build upon the work non-commercially, as long as the author is credited and the new creations are licensed under the identical terms. ©2024 Published by Scientific Scholar on behalf of Global Journal of Cataract Surgery and Research in Ophthalmology

## CASE REPORT

A 12-year-old female child reported to the Department of Ophthalmology in a Tertiary Eye Care Hospital with the chief complaints of inability to open both eyes, which were associated with lid swelling, defective vision, redness, watering and ocular pain for 1 day. Her mother gave a history of having applied custard apple seeds ground to paste to the child's hair as a remedy for dandruff. On examination, her eyes were opened with difficulty, and her visual acuity was 20/80 in the right eye and 20/120 in the left eye. Slit-lamp examination of the right eye after applying topical anaesthetic eye drops revealed conjunctival congestion and a stain-positive large corneal epithelial defect with punctate epithelial erosions [Figure 2]. The left eye revealed conjunctival congestion and a stain-positive large corneal epithelial defect with surrounding punctate epithelial erosion and loose epithelium [Figure 3]. No anterior chamber reaction was noticed in both eyes. Intraocular pressure was 11 mmHg and 12 mmHg in the right and left eyes, respectively measured by hand-held Tonopen. She was diagnosed with toxic keratoconjunctivitis in both eyes (within 6–12 h following accidental ocular exposure to the custard apple seeds). According to Dua's classification of



**Figure 2:** Slit-lamp photo of the right eye showing large epithelial defect with surrounding punctate epithelium erosions.



**Figure 3:** Slit-lamp photo of left eye showing large epithelial defect with surrounding punctate epithelium erosion and loose epithelium.

chemical injury grading, the patient was included in Grade 1 ocular chemical injury.<sup>[8]</sup>

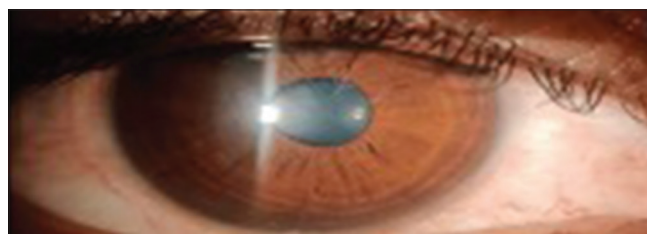
She was advised to use preservative-free moxifloxacin hydrochloride 0.5% eye drops 4 times/day, topical lubricating eye drop 8 times/day and homatropine 2% eye drops 3 times/day. She responded well to treatment, and toxic keratoconjunctivitis resolved in 3 weeks with complete restoration of vision (20/20) in both eyes [Figures 4 and 5]. She was advised to continue lubricants for a week and asked for a follow-up after 6 months.

## DISCUSSION

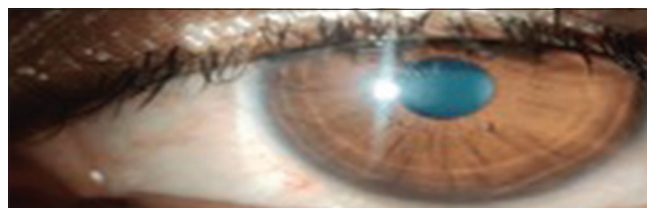
When in contact with the eyes, the liquid of the crushed custard apple seeds, which includes active chemicals, can lead to abnormalities in epithelial integrity. *A. squamosa* seed extract causes permanent unilateral or bilateral visual impairment by being toxic to ocular structures, particularly the corneal epithelium. Poor adherence of the corneal epithelium to the underlying stroma is the pathogenic mechanism.<sup>[9,10]</sup>

A case series of six patients with custard apple-induced keratopathy was reported by Nagaraja *et al.* in 2016.<sup>[11]</sup> They recommended avoiding topical steroid therapy in these patients during the acute phase before epithelial healing due to the high occurrence of secondary infections with bacteria that may harm vision. However, the rate of re-epithelialisation was not affected by topical steroids administered starting on the 3<sup>rd</sup> day following de-epithelialisation. However, if the injury is older, steroids may be given without worrying about wound healing.<sup>[12]</sup>

Two cases of custard apple-induced keratopathy have been managed with epithelium debridement, topical antibiotics and patching, according to a 2017 study by Devi Nivean *et al.*<sup>[13]</sup> Gandhi *et al.* published the largest series, in which they reported



**Figure 4:** Right eye after treatment.



**Figure 5:** Left eye after treatment.

19 similar cases.<sup>[14]</sup> According to Dutta *et al.*, routine eye patching is ineffective in the healing of mild corneal abrasions.<sup>[15]</sup> Corneal abrasions and erosions may arise from chemical exposure caused by the toxin.<sup>[9]</sup> Matrix metalloproteinase activity that is excessive can lead to the pathophysiology.<sup>[11]</sup> The abrasions get worse when the lids are constantly moving.

In this case, the patient improved significantly more quickly and experienced symptomatic relief without the need for a patch. No need for topical steroids is required. The patient did not worsen or develop any complications thereafter. Although there was no evidence to suggest an infectious aetiology, topical antibiotics were administered to stop any secondary infection that may occur. Lubricants contributed to the faster and more effective healing of the cornea. Steroids should be avoided in such cases during the acute phase before epithelial healing, as previously described by Nagaraja *et al.*<sup>[11]</sup>

## CONCLUSION

This case report highlights the importance of prevailing traditional practices. Simple health education and more public awareness of the harmful effects of custard apple seeds should be created to prevent this kind of chemical injury by focusing on the preventive aspect rather than the curative.

‘The key to avoiding chemical injuries is prevention, and our greatest weapon is health education and awareness. Traditional practices change as an outcome of increased public awareness, making safety and life protection the standard.’

## Ethical approval

Institutional Review Board approval is not required.

## Declaration of patient consent

The authors certify that they have obtained all appropriate patient consent.

## Financial support and sponsorship

Nil.

## Use of artificial intelligence (AI)-assisted technology for manuscript preparation

The authors confirm that there was no use of artificial intelligence (AI)-assisted technology for assisting in the writing or editing of the manuscript and no images were manipulated using AI.

## Conflicts of interest

There are no conflicts of interest.

## REFERENCES

1. Dastur JF. Medicinal Plants of India and Pakistan. Bombay: D.B. Taraporevala Sons; 1962.
2. Chen Y, Chen JW, Wang Y, Xu SS, Li X. Six cytotoxic annonaceous acetogenins from *Annona squamosa* seeds. Food Chem 2012;135:960-6.
3. Feinsein L. Insecticides from Plants Insects: The Year Book of Agriculture. United States: USDA; 1952.
4. Lima LA, Pimenta LP, Boaventura MA. Acetogenins from *Annona cornifolia* and their antioxidant capacity. Food Chem 2010;122:1129-38.
5. Chen Y, Wei CJ, Li X. Monotetrahydrofuran annonaceous acetogenins from the seeds of *Annona squamosa*. Phytochem Lett 2012;5:33-6.
6. Neha MS. Beneficial aspects of custard apple (*Annona squamosa*): A perspective review. Int J Res Appl Sci Eng Technol 2022;10:1108-15.
7. Miyoshi H, Ohshima M, Shimada H, Akagi T, Iwamura H, McLaughlin JL. Essential structural factors of annonaceous acetogenins as potent inhibitors of mitochondrial complex I. Biochim Biophys Acta 1998;1365:443-52.
8. Dua HS, King AJ, Joseph A. A new classification of ocular surface burns. Br J Ophthalmol 2001;85:1379-83.
9. Ramamurthi S, Rahman MQ, Dutton GN, Ramaesh K. Pathogenesis, clinical features and management of recurrent corneal erosions. Eye (Lond) 2006;20:635-44.
10. Wagoner MD. Chemical injuries of the eye: Current concepts in pathophysiology and therapy. Surv Ophthalmol 1997;41:275-313.
11. Nagaraja H, Kugar T, Shivanna Y, Agrawal A, Shetty R. Ocular toxicity by seeds of *Annona squamosa* (custard apple). Indian J Ophthalmol 2016;64:611-3.
12. Srinivasan BD. Corneal reepithelialization and anti-inflammatory agents. Trans Am Ophthalmol Soc 1982;80:758-822.
13. Devi Nivean P, Malarkodi S, Nishanth M, Nivean M. Custard apple seed induced keratitis: A harmful traditional practice in South India. GMS Ophthalmol Cases 2017;7:Doc23.
14. Gandhi P, Radhakrishnan N, Khaitan I, Srinivasan M, Prajna VN. Toxic keratitis after application of custard apple seed for head lice infestation. Cornea 2019;38:948-50.
15. Dutta SK, Deka B, Deb S, Goswami H, Ahmed T. Effectiveness of patching and non-patching in treatment of corneal abrasion: A comparative study. Indian J Clin Exp Ophthalmol 2020;6:616-21.

**How to cite this article:** Gonde (Ballamwar) P. Custard apple seeds induced toxic keratoconjunctivitis. Glob J Cataract Surg Res Ophthalmol. 2024;3:116-8. doi: 10.25259/GJCSRO\_14\_2023